

*Jerrold H. Levy, M.D., F.A.H.A., F.C.C.M., Editor*

## Management of the Traumatized Airway

Uday Jain, M.D., Ph.D., Maureen McCunn, M.D., M.I.P.P., Charles E. Smith, M.D., Jean-Francois Pittet, M.D.

**A**IRWAY injury is a major cause of early death in trauma.<sup>1,2</sup> The incidence of traumatic airway injuries is low, although it is recently increasing.<sup>3,4</sup> In contrast, mortality due to traumatic airway injuries is high, in part, because of associated injuries to other organs, which are present in about one half of the cases of blunt or penetrating airway trauma.<sup>1,2</sup> Patients with a significant injury severity (scored on a scale of 0 to 75,<sup>5</sup> which accounts for the most severely traumatized body systems) have a higher predicted mortality. In a retrospective review of 12,187 civilian patients treated at a regional trauma center in Toronto from 1989 to 2005, 36 patients (0.3%) had blunt airway trauma (injury severity score, 33; mortality, 36%) and 68 patients (0.6%) had penetrating airway trauma (injury severity score, 24; mortality, 16%).<sup>1</sup> Among 24 deaths, airway injury was the primary cause in 10 patients. Twelve patients had thoracic airway injury, 9 of whom died. In another study including 44,684 trauma patients from Texas between 1996 and 2003,<sup>2</sup> there were 19 patients (12 died) with blunt trauma and 52 patients (7 expired) with penetrating laryngeal–tracheal trauma. Traumatic airway injury is rare (incidence < 1%); thus, assessment and management are not well characterized because physicians rarely treat such cases.

Previous reviews of trauma care have addressed airway management, usually without a detailed discussion of management of patients with a traumatized airway.<sup>1,2,6–11</sup> This clinical commentary will thus review the approach to patients with airway trauma, particularly with injuries to the facial compartments (*i.e.*, maxillary and mandibular regions) and to the neck and glottis region. Care of patients with lower airway trauma, which represents thoracic trauma, will not be addressed in this review.

### Anatomy of Trauma to the Airway

Airway injuries can be divided into three types: maxillofacial, neck, and laryngeal injury.

#### Maxillofacial Trauma

Blunt or penetrating trauma to the face can affect the maxillary/mandibular or mid-facial region and extend intracranially<sup>12–14</sup> (table 1). Maxillofacial trauma can result in life-threatening airway and hemorrhage problems and lead to significant ocular, nasal, and jaw dysfunction. Bleeding may complicate airway management. Swallowing of blood clears the airway and is facilitated with the patient in the sitting position. However, gastric distension from swallowing of blood may increase the likelihood of regurgitation and aspiration. Venous bleeding can be controlled by packing and fracture reduction. Patients may not be able to control their own airway due to brisk arterial hemorrhage. Arterial bleeding may require angiographic embolization or may be resolved with surgical intervention.

In bilateral (bucket handle) or comminuted parasymphseal mandibular fractures, the tongue is no longer anchored anteriorly. This leads to posterior displacement of tongue and periglottic soft tissue, causing airway obstruction. However, this airway obstruction can be reduced by upright positioning, although a known or suspected spinal cord injury could be worsened with upright positioning. Finally, a condylar fracture fragment might be displaced through the roof of the glenoid fossa to the middle cranial fossa, thus preventing mouth opening.

Mid-facial injury can cause unilateral or bilateral Le Fort I, II, and III, and associated fractures (fig. 1). Le Fort II and III fractures may be associated with a fractured skull base and

This article is featured in "This Month in Anesthesiology," page 1A. Figures 1 to 3 were enhanced by Annemarie B. Johnson, C.M.I., Medical Illustrator, Vivo Visuals, Winston-Salem, North Carolina.

Submitted for publication September 18, 2014. Accepted for publication August 6, 2015. From the Department of Anesthesiology, Alameda Health System, Oakland, California (U.J.); Divisions of Trauma Anesthesiology and Surgical Critical Care, Department of Anesthesiology, University of Maryland School of Medicine, R Adams Cowley Shock Trauma Center, Baltimore, Maryland (M.M.); Department of Anesthesiology, Metrohealth Medical Center, Case Western Reserve University, Cleveland, Ohio (C.E.S.); and Department of Anesthesiology, University of Alabama at Birmingham, Birmingham, Alabama (J.-F.P.).

Copyright © 2015, the American Society of Anesthesiologists, Inc. Wolters Kluwer Health, Inc. All Rights Reserved. Anesthesiology 2016; 124:199–206

**Table 1.** Selected Findings in Maxillofacial Trauma

Type of injury	Findings
Dentoalveolar	Avulsed and/or fractured teeth, tongue lacerations, soft tissue swelling, oropharyngeal hemorrhage
Temporomandibular	Limitation of mouth opening (trismus vs. mechanical obstruction). Open lock anterior dislocation of condyle with drooling and difficulty swallowing, mandibular malalignment, edema, oropharyngeal bleeding
Mid-face	Skull base fractures, leakage of cerebrospinal fluid from the nose, epistaxis, soft tissue swelling, oropharyngeal hemorrhage, separation of maxillary alveolus and palate, or separation of the entire maxilla from the rest of the face
Zygomatic and orbital fractures	Retrobulbar hemorrhage, visual disturbance, and vision loss. Traumatic mydriasis. Increased intraocular pressure

Modified from the study by DeAngelis *et al.*<sup>15</sup>

leakage of cerebrospinal fluid (CSF). The cribriform plate and sphenoid sinus may be damaged in patients with nasoorbito-ethmoid fractures, Le Fort II and III fractures, or panfacial fractures. Mid-face fractures are generally associated with head and cervical spine (C-spine) injuries, whereas zygomatic and orbital fractures are associated with eye injury.<sup>15</sup>

Basilar skull fractures may involve the temporal, occipital, sphenoid, and ethmoid bones. They may lead to “raccoon eyes,” *i.e.*, periorbital ecchymosis; Battle’s sign, *i.e.*, retroauricular ecchymosis; CSF rhinorrhea; and cranial nerve palsy.

### Neck Trauma

Penetrating and blunt neck trauma may involve almost every major vital structure including respiratory, vascular, digestive, endocrine, and neurologic organs.<sup>17</sup> Findings consistent with major injury to the neck are listed in table 2. After penetrating trauma, arterial injury was reported in 12 to 13% of the cases, whereas the incidence of venous injury was found in 18 to 20% of the patients. Early deaths are generally caused by asphyxia from airway compromise or arterial hypotension from hemorrhagic shock.<sup>18</sup>

Dividing the neck into three zones (fig. 2) helps with the differential diagnosis of penetrating injuries and determination of airway management, hemorrhage control, and surgical approach.<sup>19</sup> The airway may be compressed and obstructed by tissue disruption, edema, and hematoma, which may progress after admission of the patient to the hospital.<sup>19</sup> Neck wounds should not be probed or explored in the emergency department due to the risk of dislodging a thrombus that would cause an uncontrollable hemorrhage.<sup>17</sup> C-spine injury may cause retropharyngeal hematoma leading to airway compression and difficult laryngoscopy, even in the absence of externally visible changes.<sup>20</sup> C-spine injury above C4 to C5 may

cause laryngeal edema, apnea due to loss of diaphragmatic innervation, and neurogenic shock due to decreased sympathetic tone. This complicates the management of the associated airway trauma. C-spine injury may occur in conjunction with face, neck, and head trauma, especially in patients with blunt trauma and Glasgow Coma Scale score  $\leq 8$ . Finally, a digestive tract injury should be suspected in the presence of dysphagia, retropharyngeal air, or pneumomediastinum.<sup>17</sup>

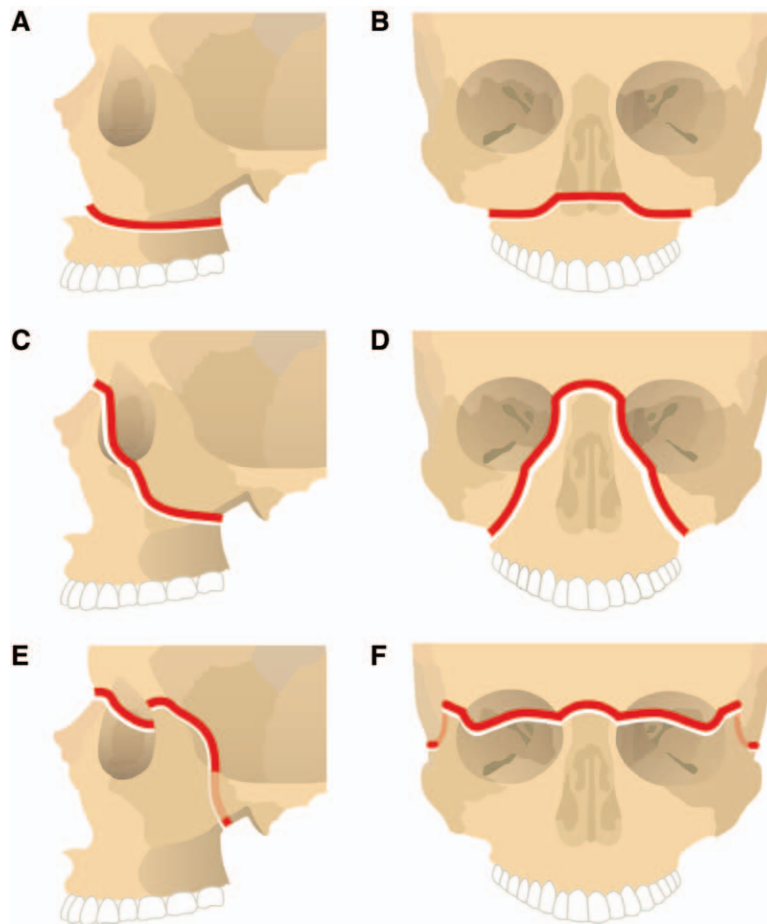
### Laryngeal Trauma

The signs, symptoms, and bronchoscopic and computed tomographic (CT) findings of laryngotracheal trauma<sup>22</sup> are presented in table 3. Signs and symptoms may not correlate with the severity of injury. Associated injuries include those to skull base, cranium, neck, C-spine, esophagus, and pharynx. Cervicothoracic vascular injuries are present in one quarter of the patients.<sup>2</sup> Blunt trauma to the larynx usually involves the trachea. Some patients with blunt injury to the anterior neck may initially appear to have a normal airway but may develop airway compromise over several hours due to an increase in laryngeal disruption, edema, and hematoma. Time from injury—to include prehospital transport—as opposed to time since admission should be a consideration in the decision to intubate or to observe the patient. Other patients may have self-limiting injuries, not requiring tracheal intubation or laryngeal surgery.<sup>22</sup> Tracheal compromise by compression or direct injury should be suspected if there is airway obstruction, stridor, or trauma to the neck, sternum, or clavicle.<sup>8–11,23</sup>

Laryngeal–tracheal separation may occur. Insertion of an endotracheal tube (ETT) may also cause separation of a trachea tenuously held to the larynx. Sudden deceleration causing flexion–extension of the neck can lead to shearing, primarily at the cricoid and carina as they are anchored to adjacent structures (fig. 3). Blunt trauma may crush the trachea against the vertebral bodies, transecting tracheal rings and the cricoid cartilage, causing a “clothesline” injury. A transected cervical trachea may retract into the mediastinum and will need to be surgically extracted. Other causes of blunt airway trauma are steering wheel or bicycle handlebar injury and hanging. Finally, an increased intrathoracic pressure due to chest compression against a closed glottis can tear the posterior membranous trachea.

### Initial Care

In the United States, prehospital trauma care is usually provided by the Emergency Medical System staffed primarily by emergency medical technicians and paramedics.<sup>6</sup> In some countries, physicians lead prehospital care.<sup>24</sup> The choice between temporizing at the scene *versus* definitive airway and other prehospital interventions is guided by triage, availability of expertise and equipment in the pre-hospital *versus* hospital settings, and travel time to the hospital. In many areas, statewide and region-specific guidelines exist that specify



**Fig. 1.** Le Fort fractures. (A, B) Le Fort I fracture. Drawings in lateral (A) and frontal (B) projections show Le Fort I fracture runs horizontally above maxillary alveolar process. Pterygoid plates are broken, as is true in all types of Le Fort fracture. Walls of maxillary sinuses in this plane are broken, including point at anterolateral margin of nasal fossa. Maxillary teeth would be movable on physical examination relative to remainder of face. (C, D) Le Fort II fracture. Drawings show plane of Le Fort II fracture in lateral (C) and frontal (D) projections. Le Fort II fracture is pyramidal in shape with teeth at base of pyramid and nasofrontal suture at the apex of pyramid. Pterygoid plates are broken, as is true in all types of Le Fort fracture. Posterior and lateral walls of maxillary sinus are broken as fracture skirts inferior in relation to body of zygoma. Fracture then crosses inferior orbital rim, orbital floor, and medial wall of orbit before crossing midline near nasofrontal suture. Maxillary teeth and nose as a unit would be movable relative to zygomata and rest of skull. (E, F) Le Fort III fracture. Drawings show plane of Le Fort III fracture in lateral (E) and frontal (F) projections. Le Fort III fracture separates the bones of face from the rest of skull. Pterygoid plates are broken, as is true in all types of Le Fort fracture. Upper posterior margins of maxillary sinuses fracture, as does zygomatic arch, lateral orbital wall, and lateral orbital rim. There is a fracture near junction of frontal bone and greater wing of sphenoid in posterior aspect of orbit, fracture along medial orbital wall, and fracture across nasofrontal suture. Maxillary teeth, nose, and zygomata as a unit would be movable on physical examination relative to the rest of skull. Modified from the study by Rhea *et al.*<sup>16</sup>

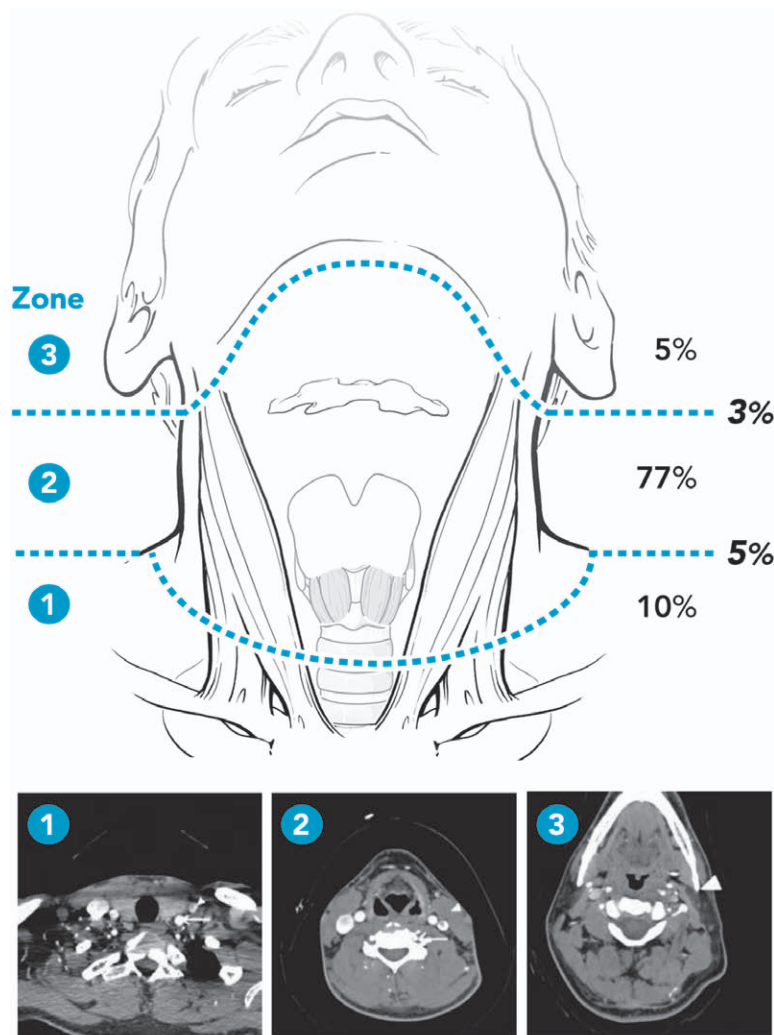
**Table 2.** Findings Consistent with Major Injury after Penetrating and Blunt Neck Trauma

Active external bleeding from the wound
Dysphagia, hoarseness, stridor
Disruption of larynx or trachea
Bleeding into the tracheobronchial tree
Subcutaneous emphysema
Expanding hematoma
Large or pulsatile hematoma
Oropharyngeal bleeding
Sucking neck wound
Neurologic deficit (spinal cord, brachial plexus)

Modified from the study by Britt and Peyser.<sup>17</sup>

protocols for prehospital personnel (<http://www.miemss.org/home/ems-providers>, accessed October 28, 2015). Airway management is impacted by associated injuries to other organs and the condition of the patient. If oxygenation and ventilation can be maintained, prehospital establishment of a definitive airway may not be required and may potentially be detrimental.<sup>7,25,26</sup> Care of injuries to other organs and management of hemorrhage is limited in the prehospital setting, even in the presence of a physician. Hence, a noncritical airway intervention should not delay transport to the hospital.

If prehospital expertise and equipment is comparable to that in the hospital, if there are prehospital personnel who are trained and experienced in airway management,



**Fig. 2.** Neck zones for evaluating and treating penetrating and blunt neck trauma. The neck is commonly divided into three distinct zones, which facilitates initial assessment and management based on the limitations associated with surgical exploration and hemorrhage control unique to each zone. The axial computed tomographic images (*bottom*) correspond to zone 1, zone 2, and zone 3. The numbers represent the percentage of injury to each zone of the neck. Zone 1: Clavicles to cricoid: High-risk zone because of the presence of great vessels, lung, and trachea. Zone 2: Cricoid to mandibular angle: Most frequently injured, but surgical access is easier. Hemorrhage is easier to control as the great vessels are not anchored to adjoining structures, unlike in zones 1 and 3. Zone 3: Mandibular angle to skull base: High risk as surgical access is difficult. Angiographic intervention is frequently used. Modified from the study by Salinas and Brennan.<sup>21</sup>

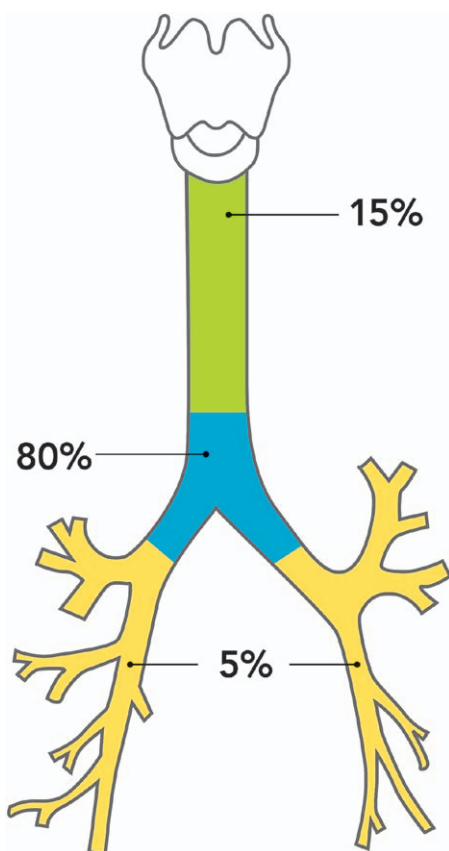
**Table 3.** Selected Findings in Laryngotracheal Trauma

Signs and symptoms: Subcutaneous emphysema, crepitus, air escape, external bleeding and bruising, ecchymosis, hematoma, dyspnea, hypopnea, stridor, wheezing, cough, dysphonia, hoarseness, pain with phonation, dysphagia, drooling, hemoptysis, tracheal deviation, nerve injury
Bronchoscopic findings: Tear, edema, hematoma, abnormality of vocal cords, compression or distortion of airway. Note: Tracheal injury may be exterior to the visible mucosa and evidence of injury may not be seen with fiberoptic bronchoscopy
Computed tomography findings: Compression or distortion of airway and surrounding structures, fracture, tear, edema, hematoma, abnormal air pockets

or if the travel time to the hospital is long, definitive airway management may be performed as soon as indicated. Hence, depending on the urgency and facilities, a traumatized airway that needs securing may be controlled in the field, during transport, in the hospital trauma bay, or in the operating room. Allotment of resources for prehospital

care may be proportionately higher in settings with long travel time to the hospital. For example, in the Toronto study, 31% of the airways were secured at the scene or en route, 21% at an outside hospital, 16% in the emergency department of the regional trauma center, and 29% in the operating room.<sup>1</sup>





**Fig. 3.** Sites and incidence of tracheobronchial disruption after blunt traumatic injury to the airway. Adapted from the study by Wilson,<sup>13</sup> with permission. Adaptations are themselves works protected by copyright. So in order to publish this adaptation, authorization must be obtained both from the owner of the copyright in the original work and from the owner of copyright in the translation or adaptation.

## Airway Management

### Evaluation of the Traumatized Airway

Protective gear may be necessary for care providers. Airway trauma may not be readily apparent, and its evaluation requires a high level of suspicion for airway disruption and compression. Airway examination should be as complete as possible but may be limited by lack of time and patient cooperation, neck immobilization, and injury in and around the airway. History and physical examination should help determine mechanism of injury, extent of associated injuries, degree of shock, and previous interventions (table 4). Excessive bleeding in and around the airway or a rapidly expanding hematoma (*e.g.*, neck area with compromised airway) may be due to anticoagulant medication. Currently, it is difficult to reverse the effect of some newer anticoagulants, thus increasing the risk.

When the airway compromise is due to tissue disruption, edema and hematoma may worsen over time. Thus, the airway should be reevaluated frequently, at least for several hours. Significant findings associated with maxillofacial, neck, and laryngotracheal trauma are bleeding, bruising,

hematoma, disruption of bony and soft tissues, edema, air leak, and subcutaneous emphysema and are summarized in tables 1 to 3.<sup>1</sup> Inspiratory stridor suggests impending loss of airway. Ability to speak and answer simple questions indicates a patent airway, enough respiratory effort to generate voice, and enough blood pressure to perfuse the brain.<sup>22</sup>

If time permits, a history and physical examination should be performed in every patient whenever feasible, before the initiation of anesthetic care and airway management. However, the Advanced Trauma Life Support Manual<sup>27</sup> espouses three underlying concepts: (1) treat the greatest threat to life first, (2) the lack of a definitive diagnosis should never impede the application of an indicated treatment, and (3) a detailed history is not essential to begin the evaluation of a patient with acute injuries.<sup>27</sup> Evaluation of the traumatized airway and adjoining structures may use direct laryngoscopy (DL), videolaryngoscopy (VL), fiberoptic bronchoscopy (FOB), or ultrasonic imaging, with or without sedation and topical anesthesia. Radiographic evaluation including CT and magnetic resonance imaging can be performed if intubation is not emergent or once the airway has been secured. Imaging provides comprehensive information about airway and surrounding structures and is especially suitable for evaluating the risk of airway compression.

### General Approach

There is a paucity of evidence regarding the management of patients with traumatized airway. Initially, 100% oxygen is administered, the airway is cleared of material (*e.g.*, dentures, loose teeth, tissue, blood, and vomitus), and basic maneuvers are done: suction, chin lift, jaw thrust, oral airway, and bag-mask ventilation may all be necessary. A supraglottic airway may be cautiously utilized to enhance airway patency in obtunded patients, especially in the field. If a cervical injury is suspected, all maneuvers must be performed with due caution (*e.g.*, manual in-line immobilization, cervical collar). Nasal airways should be avoided if there is a possibility of basilar skull or nasal fracture. If a large vessel has been injured, supine or Trendelenburg position will minimize the risk of air embolism. In patients with facial fractures, positive-pressure face mask ventilation may displace the facial bone fragments, worsen airway obstruction, and aggravate subcutaneous emphysema, pneumoencephalus, pneumomediastinum, and pneumothorax. In some instances, the face mask will improve the situation because it serves as a “splint” to stabilize facial fractures that have resulted in unwanted motion of facial structures. Laryngeal injuries may be extended by cricoid pressure, rigid laryngoscopy, intubating stylets, blind techniques, and even by the ETT. This may result in avulsion of mucous membranes and creation of a pseudolumen or a false passage.

A certain percentage of patients with limited airway injury do not require intubation.<sup>1,2</sup> In one study,<sup>2</sup> a definitive airway was emergently required in approximately 50% of the penetrating trauma cases and 80% of blunt trauma cases. In another study,<sup>1</sup> about a third of the intubations were performed in the operating room, indicating that they were

**Table 4.** Evaluation of the Patient with a Traumatized Airway

---

Check for symptoms and signs of respiratory distress (e.g., tachypnea, hypoxia, altered mental status, pneumothorax)
Look for symptoms and signs of shock (e.g., tachycardia, hypotension, altered mental status, tachypnea, decreased pulse pressure)
Perform a standard airway evaluation as time and patient cooperativeness permits
Remember the risk of aspiration
Determine the mechanism of trauma (e.g., blunt vs. penetrating)
Evaluate for associated injuries (e.g., head, neck, spine, thorax, musculoskeletal)
Evaluate any structural damage to the airway (e.g., laryngotracheal, maxillofacial, penetrating neck wound, thermal injury)

---

not emergent. Thus, conservative management is suitable for stable patients without airway compromise. If intubation is not performed, the patient should be frequently reassessed.

Indications for urgently securing the airway include severe trauma, cardiac arrest, shock, respiratory distress, hypoxia, severe agitation, and inability to protect the airway, *i.e.*, low Glasgow Coma Scale score ( $\leq 8$ ) and altered mental status. Esophageal injury is present in up to 10% of patients with laryngotracheal trauma, especially penetrating trauma.<sup>2</sup> Patients with esophageal injury should be intubated urgently. Early airway control should also be considered in cases of hematoma that may expand in or around airway, and injury due to chemical, biological, or inhalational agents, including smoke and burns that cause mucosal edema. A surgical airway is indicated in the hypoxic or hypotensive patient who cannot be orally intubated.

Various techniques of intubation including DL, VL, and FOB are suitable. Spontaneous ventilation is desirable in difficult airway situations in cooperative patients and can be facilitated by topical anesthesia, judicious sedation, patient cooperation, and removal of vomitus, blood, and debris. Rapid sequence induction (RSI) and intubation utilizing manual in-line axial stabilization of the head and neck (if indicated) is the alternative.<sup>1</sup> RSI can be successfully used in patients with penetrating neck trauma.<sup>19</sup> Indeed, in a study of 12,187 civilian trauma patients, RSI was used in 70% of the patients with airway trauma.<sup>1</sup>

Intubation during spontaneous ventilation in an awake or a sedated patient avoids positive-pressure ventilation, affords more time for intubation before oxygen desaturation (if adequate preoxygenation has occurred), and allows more complete inspection of the airway. In cooperative patients, it may be safer if unknown airway disruption exists or if intubation is difficult. RSI is usually faster and more suitable for uncooperative or hemodynamically unstable patients with major injuries to other organs. The equipment and personnel to perform RSI is generally more readily available in all locations. The choice between primary surgical airway, awake/spontaneous breathing intubation, RSI, and watchful waiting without intubation is a clinical decision that depends on patient's condition, clinical setting, type and severity of airway and systemic injuries, and available personnel, equipment, and expertise. VL may be combined with FOB or an airway exchange catheter.<sup>28</sup> VL can guide the FOB by visualizing the larynx and the tip of the FOB.<sup>28</sup> VL with a channeled blade requires less pharyngeal retraction than that with a nonchanneled blade and may be preferable in the setting of airway trauma.<sup>28</sup> FOB is suitable in the presence of

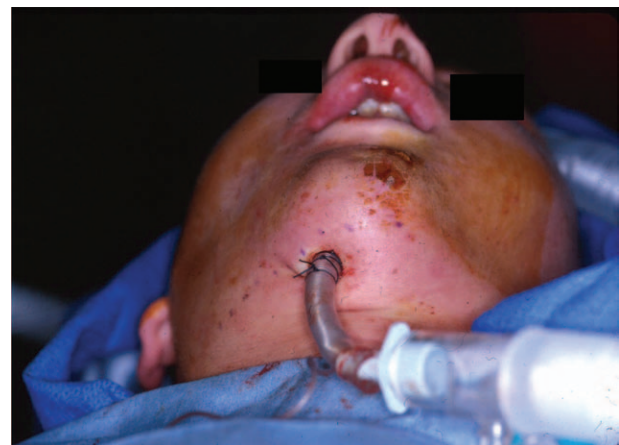coexisting difficult mask ventilation as well as difficult intubation, encountered in facial trauma and other situations. Its flexibility may be desirable for nasal intubation and in the presence of airway or C-spine trauma. FOB is preferable if airway access is limited as during intubation in the prone or lateral position or in the presence of neurosurgical fixation with a surgical halo device. The use of FOB is limited by blood, mucous, and inability to displace debris.

Inability to intubate necessitates a surgical airway and is supported by both the American Society of Anesthesiologists Difficult Airway Algorithm modified for trauma 2014 and the American Society of Anesthesiologists Taskforce on Management of the Difficult Airway.<sup>29,30</sup> Hence, all necessary airway equipment and personnel should be immediately available.

## Specific Situations

### Facial Trauma

Mandibular and zygomatic arch injuries can cause trismus that may resolve with neuromuscular blockade. Condylar



**Fig. 4.** Submental intubation. The patient had bilateral mandibular, maxillary, and nasal bone fractures; a nasal intubation was contraindicated. After induction of anesthesia and orotracheal intubation with an armored endotracheal tube (ETT), the surgeons incised the mucosal and external submandibular area and then pulled the ETT through the floor of the mouth to the submandibular area, reattaching the connector. If the patient is to remain in mandibular–maxillary fixation (MMF), he can be extubated from this location. If MMF is released at the end of the case, the ETT is returned to the oropharynx and extubation proceeds as usual: in the operating room, the postanesthesia care unit, or the intensive care unit.

**Table 5.** Key Points for Managing a Patient with a Traumatized Airway

There is a lack of evidence regarding the best practice for airway management in patients with a traumatized airway. Practitioners should thus utilize the technique with which they are most competent.

A high degree of suspicion for airway disruption, or a difficult airway due to the presence of blood, vomitus, secretions, or tissue edema, should alert the anesthesiologist to consider alternative approaches, such as maintenance of spontaneous breathing and/or the need for a controlled surgical airway.

Inability to intubate is an absolute indication for an emergency cricothyrotomy or surgical tracheostomy and is not a failure on the part of the anesthesiologist. This may be the most appropriate initial approach to airway management in selected airway injuries.

fractures may limit jaw opening because of actual mechanical blockage produced by displacement of a bony fragment. Surgical intervention may be required to dislodge the fragment (table 1). Conversely, bilateral mandibular fractures may ease laryngoscopic retraction. Mid-face fractures with a compromised airway may require a surgical airway, which also facilitates surgical access to the face. Alternatively, with submental intubation, the ETT exits from an incision in the floor of mouth (fig. 4). Avulsed permanent teeth should be replanted as soon as possible after intubation.

Nasal intubation is rarely performed acutely because of the risk of basilar skull injury. In the presence of a fractured skull base, nasal cannula and delivery of high-flow oxygen *via* FOB increase the risk of intracranial infection. Nasal intubation is primarily used for nonemergent oral and maxillofacial surgery. Nasal intubation using FOB is suitable if the fracture does not cross the midline and the cribriform plate is intact on CT imaging. In cases of frontobasal fractures with CSF fistula, nasal intubation has not been found to be associated with meningitis.<sup>31</sup>

### Neck Trauma with Extrinsic Airway Compression

Airway manipulation might dislodge a hematoma and thus increase bleeding and/or tissue edema. Surgical release of the overlying tissue may reduce compression but may increase bleeding. RSI minimizes the risk of expansion of a hematoma due to coughing and bucking but may worsen airway obstruction. Intubation during spontaneous ventilation is also suitable. A surgical airway may be urgently required should RSI be unsuccessful.

### Laryngeal–Tracheal Disruption

If the airway injury is large or subglottic, a surgical airway may be the best initial approach. In some patients, it may be possible to insert an ETT through the wound.<sup>1</sup> Alternatively, FOB may be used to pass the ETT distal to the site of disruption while avoiding further injury. Spontaneous ventilation is desirable. Conventional DL is risky in the presence of partial separation or avulsions of larynx and trachea.<sup>22</sup>

### Summary

There is a lack of evidence-based approach regarding the best practice for airway management in patients with a traumatized airway. General recommendations for the management of the traumatized airway are summarized in table 5. Airway trauma may not be readily apparent, and its

evaluation requires a high level of suspicion for airway disruption and compression. For patients with facial trauma, control of the airway may be significantly impacted by edema, bleeding, inability to clear secretions, loss of bony support, and difficulty with face mask ventilation. With the airway compression from neck swelling or hematoma, intubation attempts can further compromise the airway due to expanding hematoma. For patients with airway disruption, the goal is to pass the tube across the injured area without disrupting it or to insert the airway distal to the injury using a surgical approach.

If airway injury is extensive, a surgical airway distal to the site of injury may be the best initial approach. Alternatively, if orotracheal intubation is chosen, spontaneous ventilation may be maintained or RSI may be performed. RSI is a common approach. Thus, some of the patients intubated may subsequently require tracheostomy. A stable patient with limited injuries may not require intubation but should be watched carefully for at least several hours.

Because of a paucity of evidence-based data, the choice between these approaches and the techniques utilized is a clinical decision depending on the patient's condition, clinical setting, injuries to airway and other organs, and available personnel, expertise, and equipment. Inability to obtain a definitive airway is always an absolute indication for an emergency cricothyroidotomy or surgical tracheostomy.

### Acknowledgments

This study was supported by the Department of Anesthesiology, Alameda Health System, Oakland, California; Department of Anesthesiology, University of Maryland School of Medicine, Baltimore, Maryland; Metrohealth Medical Center, Case Western Reserve University, Cleveland, Ohio; and University of Alabama at Birmingham, Birmingham, Alabama.

### Competing Interests

The authors declare no competing interests.

### Correspondence

Address correspondence to Dr. Pittet: Department of Anesthesiology, University of Alabama at Birmingham, 619 South 19th Street, Jefferson Tower 926, Birmingham, Alabama 35249. [pittetj@uab.edu](mailto:pittetj@uab.edu). Information on purchasing reprints may be found at [www.anesthesiology.org](http://www.anesthesiology.org) or on the masthead page at the beginning of this issue. ANESTHESIOLOGY's articles are made freely accessible to all readers, for personal use only, 6 months from the cover date of the issue.



## References

1. Kummer C, Netto FS, Rizoli S, Yee D: A review of traumatic airway injuries: Potential implications for airway assessment and management. *Injury* 2007; 38:27–33
2. Bhojani RA, Rosenbaum DH, Dikmen E, Paul M, Atkins BZ, Zonies D, Estrera AS, Wait MA, Meyer DM, Jessen ME, DiMaio JM: Contemporary assessment of laryngotracheal trauma. *J Thorac Cardiovasc Surg* 2005; 130:426–32
3. VandeGriend ZP, Hashemi A, Shkoukani M: Changing trends in adult facial trauma epidemiology. *J Craniofac Surg* 2015; 26:108–12
4. Rallis G, Stathopoulos P, Igoumenakis D, Krasadakis C, Mourouzis C, Mezitis M: Treating maxillofacial trauma for over half a century: How can we interpret the changing patterns in etiology and management? *Oral Surg Oral Med Oral Pathol Oral Radiol* 2015; 119:614–8
5. Baker SP, O'Neill B, Haddon W Jr, Long WB: The injury severity score: A method for describing patients with multiple injuries and evaluating emergency care. *J Trauma* 1974; 14:187–96
6. Como JJ, Smith CE, Grabinsky A: Trauma epidemiology, mechanisms of injury, and prehospital care, *Essentials of Trauma Anesthesia*. Edited by Varon AJ, Smith CE. Cambridge, Cambridge University Press, 2012, pp 1–15
7. Hussmann B, Lefering R, Waydhas C, Ruchholtz S, Wafaisade A, Kauther MD, Lendemans S: Prehospital intubation of the moderately injured patient: A cause of morbidity? A matched-pairs analysis of 1,200 patients from the DGU Trauma Registry. *Crit Care* 2011; 15:R207
8. Tobin JM, Varon AJ: Review article: Update in trauma anesthesiology: Perioperative resuscitation management. *Anesth Analg* 2012; 115:1326–33
9. Mayglothling J, Duane TM, Gibbs M, McCunn M, Legome E, Eastman AL, Whelan J, Shah KH: Eastern Association for the Surgery of Trauma: Emergency tracheal intubation immediately following traumatic injury: An Eastern Association for the Surgery of Trauma practice management guideline. *J Trauma Acute Care Surg* 2012; 73(5 suppl 4):S333–40
10. Stephens CT, Kahntroff S, Dutton RP: The success of emergency endotracheal intubation in trauma patients: A 10-year experience at a major adult trauma referral center. *Anesth Analg* 2009; 109:866–72
11. Abernathy JH III, Reeves ST: Airway catastrophes. *Curr Opin Anaesthesiol* 2010; 23:41–6
12. Kaslow O, Gollapudy S: Anesthetic considerations for ocular and maxillofacial trauma, *Essentials of Trauma Anesthesia*. Edited by Varon AJ, Smith CE. New York, Cambridge University Press, 2012, pp 198–208
13. Wilson WC: Trauma airway management, *Trauma Anesthesia*. Edited by Smith CE. New York, Cambridge University Press, 2008, pp 9–54
14. Parekh KP, Ash CS: Oral and maxillofacial trauma, *Trauma Anesthesia*. Edited by Smith CE. New York, Cambridge University Press, 2008, pp 417–30
15. DeAngelis AF, Barrowman RA, Harrod R, Nastri AL: Review article: Maxillofacial emergencies: Maxillofacial trauma. *Emerg Med Australas* 2014; 26:530–7
16. Rhea JT, Mullins ME, Novelline RA: The face, *Radiology of Skeletal Trauma*, 3rd edition. Vol. 1. Edited by Rogers LF. Philadelphia, Churchill Livingstone, 2002, pp 315–75
17. Britt LD, Peyser MD: Penetrating and blunt neck trauma, *Trauma*. Edited by Mattox KL, Feliciano DV, Moore EE. New York, McGraw-Hill, 2000, pp 437–49
18. Ledgerwood AM, Lucas CE: Neck: Vessels, *The Textbook of Penetrating Trauma*. Edited by Ivatury RR, Cayten CG. Baltimore, Williams and Wilkins, 1996, pp 488–96
19. Mandavia DP, Qualls S, Rokos I: Emergency airway management in penetrating neck injury. *Ann Emerg Med* 2000; 35:221–5
20. Crosby ET: Airway management in adults after cervical spine trauma. *ANESTHESIOLOGY* 2006; 104:1293–318
21. Salinas NL, Brennan JA: Penetrating and blunt neck trauma, *Resident Manual of Trauma to the Face, Head and Neck*. Alexandria, American Academy of Otolaryngology-Head and Neck Surgery Foundation, 2012, pp 164–73
22. Schaefer SD: Management of acute blunt and penetrating external laryngeal trauma. *Laryngoscope* 2014; 124:233–44
23. Pierre EJ, McNeer RR, Shamir MY: Early management of the traumatized airway. *Anesthesiol Clin* 2007; 25:1–11, vii
24. Yeguiayan JM, Garrigue D, Binquet C, Jacquot C, Duranteau J, Martin C, Rayeh F, Riou B, Bonithon-Kopp C, Freysz M; French Intensive Care Recorded In Severe Trauma Study Group: Medical pre-hospital management reduces mortality in severe blunt trauma: A prospective epidemiological study. *Crit Care* 2011; 15:R34
25. Wang HE, Abo BN, Lave JR, Yealy DM: How would minimum experience standards affect the distribution of out-of-hospital endotracheal intubations? *Ann Emerg Med* 2007; 50:246–52
26. von Elm E, Schoettker P, Henzi I, Osterwalder J, Walder B: Pre-hospital tracheal intubation in patients with traumatic brain injury: Systematic review of current evidence. *Br J Anaesth* 2009; 103:371–86
27. American College of Surgeons: *Advanced Trauma Life Support Manual*, Ninth edition. Chicago, American College of Surgeons, 2012, pp 2–28
28. Jain U, Kaslow O, Dagal A: Recent developments in airway management. *ASA Newsletter* 2015; 79(6):66–8
29. Hagberg CA, Kaslow O: Difficult airway management algorithm in trauma updated by COTEP. *ASA Newsletter* 2014; 78(9):56–60
30. Practice guidelines for management of the difficult airway. An updated report by the American Society of Anesthesiologists Task Force on Management of the Difficult Airway. *ANESTHESIOLOGY* 2013; 118: 1–20
31. Bähr W, Stoll P: Nasal intubation in the presence of fronto-basal fractures: A retrospective study. *J Oral Maxillofac Surg* 1992; 50:445–7