

## Perioperative Management of Pheochromocytoma

Michelle A.O. Kinney, MD, Bradly J. Narr, MD, and Mark A. Warner, MD

**P**HEOCHROMOCYTOMAS ARE pharmacologically volatile, potentially lethal catecholamine-containing tumors of chromaffin tissue.<sup>1</sup> They are usually found in the adrenal medulla, but they may occur wherever chromaffin tissue is located. Chromaffin cells are associated with the celiac, mesenteric, renal, adrenal, hypogastric, testicular, and paravertebral sympathetic nerve plexus. The major sites where pheochromocytomas occur are the adrenal medulla (90%), the paraganglia cells of the sympathetic nervous system, and the organ of Zuckerkandl.<sup>2</sup> Approximately 10% of sporadic and 50% of familial adrenal tumors are bilateral, and approximately 10% of pheochromocytomas are multiple in location at the time of presentation.<sup>3</sup>

Paragangliomas are derived from neural crest cells that migrate in close association with autonomic ganglion cells, and all paragangliomas have the capacity to secrete catecholamines.<sup>4,5</sup> Functional paragangliomas that secrete norepinephrine can occur and present similarly to pheochromocytoma. The proportion of catecholamine-secreting paragangliomas is thought to be high for adrenal pheochromocytomas, intermediate for aorticosympathetic and viscerautonomic tumors, and low for paragangliomas of the head and neck, also known as *glomus tumors*.<sup>5</sup> Paragangliomas may present as painless swellings in the neck overlying the carotid bifurcation. These are also called *carotid body tumors* or *chemodectomas*.<sup>5</sup> Of paragangliomas, <10% are malignant, but they can be locally invasive and can cause cranial nerve palsies.<sup>4</sup>

The resection of a pheochromocytoma or biochemically active paraganglioma has great potential for intraoperative and postoperative complications owing to release of catecholamines during manipulation of the tumor. Significant hemodynamic and metabolic effects are associated with a sudden decrease in catecholamine levels after removal of a tumor.<sup>6</sup> In a series of 138 patients undergoing resection of pheochromocytoma tumors in a variety of anatomic locations between 1926 and 1970, surgical mortality was 2.9%.<sup>7</sup> Desmonts et al<sup>8</sup> reported a 3.9% mortality rate in their series of 102 patients between 1964 and 1976. A more recent series of 143 patients who underwent pheochromocytoma or paraganglioma resection showed no mortality and the absence of perioperative myocardial infarctions or cerebrovascular accidents.<sup>9</sup> Advances in localization techniques, medical management, and anesthetic management have resulted in improved surgical outcomes.<sup>10</sup>

### PRESENTATION

Hypertension is the most common sign in patients presenting with pheochromocytoma; however, only 1 in 400 to 800 hypertensive patients has a pheochromocytoma.<sup>11</sup> The 3 most commonly experienced symptoms are headache, excessive sweating, and palpitations. Symptoms may be provoked by postural changes, exercise, anxiety, trauma, pain, or certain medications.<sup>2</sup>

A substantial proportion of pheochromocytomas secrete predominantly norepinephrine, sometimes paroxysmally but usually sustained; sustained hypertension is the most common presentation for pheochromocytoma. Some patients present with hyperglycemia as a result of glycogenolysis and impaired insulin release by pancreatic islet cells. Approximately 10% to 17% of patients present with paroxysmal symptoms reflecting excessive secretion of epinephrine and dopamine, including palpitations, trembling, sweating and blanching, and feelings of panic and doom.<sup>11</sup>

Most, but not all,<sup>12</sup> patients with pheochromocytoma or paraganglioma presenting to the anesthesiologist already have been diagnosed. In 1 series,<sup>9</sup> only 3 of 143 patients who underwent surgical excision of pheochromocytoma or paraganglioma had not been diagnosed preoperatively. None of the undiagnosed or diagnosed patients died perioperatively or experienced a myocardial infarction or cerebrovascular event.

Pheochromocytoma multisystem crisis is an unusual and life-threatening presentation that consists of multiple organ system failure, temperature often >40°C, encephalopathy, and hypertension or hypotension. Successful treatment demands prompt diagnosis, vigorous medical preparation, and emergency tumor removal if the patient's condition continues to deteriorate.<sup>13</sup>

---

From the Department of Anesthesiology, Mayo Clinic, Rochester, MN.

Internally supported by Mayo Foundation.

Address reprint requests to Michelle A. O. Kinney, MD, Charlton 1-145, Mayo Clinic, 200 First Street, SW, Rochester, MN 55905.  
E-mail: kinney.michelle@mayo.edu

Copyright 2002, Elsevier Science (USA). All rights reserved.

1053-0770/02/1603-0020\$35.00/0

doi:10.1053/jcan.2002.124150

Key words: pheochromocytoma, paraganglioma, catecholamine, adrenal gland neoplasms, intraoperative care, preanesthetic medication, postoperative care

### Familial Versus Sporadic Presentations

Pheochromocytomas are usually classified as being sporadic or familial in origin. Familial conditions associated with pheochromocytoma include simple familial pheochromocytoma, multiple endocrine neoplasia (MEN) IIA and IIB, the neuroectodermal syndromes of neurofibromatosis, von Hippel-Lindau syndrome, tuberous sclerosis, and Sturge-Weber syndrome.<sup>3</sup> Patients with familial pheochromocytoma are predisposed to having multiple or bilateral adrenal tumors.<sup>14</sup> Partial adrenalectomy is gaining enthusiastic support in familial forms of pheochromocytoma.<sup>15</sup>

### Multiple Endocrine Neoplasia IIA

MEN IIA (Sipple's syndrome) includes medullary carcinoma of the thyroid, hyperparathyroidism, and pheochromocytoma.<sup>3</sup> Pheochromocytomas in this syndrome are frequently bilateral.<sup>11</sup> Urinary screening reveals a higher incidence of epinephrine-secreting tumors in MEN IIA than in sporadic pheochromocytoma.<sup>11</sup> MEN IIB is associated with medullary carcinoma of the thyroid, mucosal neuromas, intestinal ganglioneuromas, marfanoid habitus, and hyperparathyroidism.<sup>3</sup> Pheochromocytomas in patients with MEN IIB are rarely bilateral or malignant.<sup>11</sup>

### von Hippel-Lindau Syndrome (Retinal Cerebellar Hemangioblastomatosis)

This rare syndrome may include pheochromocytoma and retinal angiomas (von Hippel disease), cerebellar hemangioblastoma (Lindau disease), pancreatic cysts, renal cysts and carcinoma, and epididymal cystadenoma.<sup>11</sup> In patients with adrenal pheochromocytoma, MEN II (type A or B) patients experienced more symptoms than von Hippel-Lindau patients, and MEN II patients had a higher incidence of hypertension and higher plasma concentrations of metanephrines, but had lower total plasma concentrations of catecholamines than von Hippel-Lindau patients. Mutation-dependent differences in the expression of genes controlling catecholamine synthesis explain the differences in clinical presentation of pheochromocytoma in patients with MEN II and von Hippel-Lindau syndrome.<sup>16</sup>

### von Recklinghausen Disease (Neurofibromatosis)

There are 2 variants of neurofibromatosis, type 1 and type 2. Type 1 neurofibromatosis is a rare autosomal dominant disorder in which neurofibromas arise along peripheral nerves; 1% of these patients develop pheochromocytoma. The type 2 variant is associated with neurofibromas arising in proximity to the cochlear branch of the eighth cranial nerve. It is not associated with pheochromocytoma.<sup>17</sup> In general, the clinical association of café-au-lait spots and neurofibromas should increase the anesthesiologist's suspicion of the possible existence of a pheochromocytoma.<sup>11</sup>

### Cardiac Pheochromocytoma

Of all pheochromocytomas, 10% are located outside the adrenal glands.<sup>18</sup> Intrathoracic pheochromocytomas comprise only 1% of all cases of pheochromocytoma.<sup>19</sup> Cardiac pheo-

chromocytomas are quite rare. Approximately 30 cases have been reported in the literature.<sup>20</sup> Cardiac pheochromocytomas most frequently arise from the left atrium, followed by the interatrial septum, the anterior surface of the heart, and the intrapericardial aorta and pulmonary artery. The cardiac blood supply is parasitized by these tumors.<sup>21</sup> Catecholamine-secreting cardiac tumors present with hypertension, orthostatic hypotension, headaches, palpitations, anxiety, excessive perspiration, pallor, chest and abdominal pain, paresthesia, weakness, and weight loss.<sup>21</sup> Compressive dysphagia has also been reported.<sup>22</sup> Pericardial tamponade or superior vena cava obstruction may be the presenting symptoms of a paraganglioma without catecholamine secretion.<sup>21</sup>

### Pregnancy

Pheochromocytoma can mimic toxemia during pregnancy.<sup>11</sup> In unprepared patients, spontaneous labor with vaginal delivery can be disastrous for the mother and fetus and should be avoided. Treatment with adrenergic blocking agents should be employed. Although its safety has not been established,  $\alpha$ -adrenergic blockade has been used in many cases without obvious adverse effect. In early or middle pregnancy, the tumor should be removed after adequate  $\alpha$ -adrenergic blockade is established. The risk of spontaneous abortion at the time of surgery is considerable.<sup>17</sup> Late in pregnancy, if the fetus has not reached sufficient size, the patient should be treated with  $\alpha$ -adrenergic blockade by oral administration of phenoxybenzamine until the fetus has reached maturity.<sup>23,24</sup> If the fetus is adequately developed, cesarean section followed by excision of the tumor may be performed.<sup>17</sup>

### Pediatrics

Pheochromocytoma is an extremely rare tumor in children. Preoperative and intraoperative management should follow the same principles as for adults.<sup>11</sup> Multiple and extra-adrenal tumors are more common in children (35%) than in adults

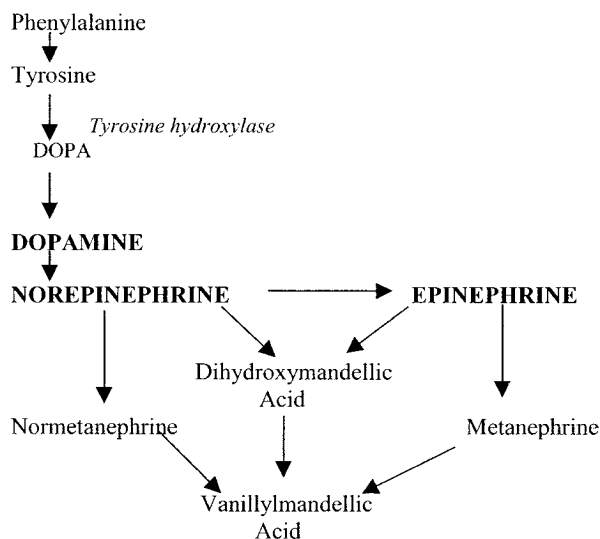


Fig 1. Synthesis and metabolism of catecholamines.

(8%).<sup>2</sup> This pattern makes localization and surgical management more challenging. Hack<sup>25</sup> described preoperative preparation with phenoxybenzamine in initial doses of 0.25 to 1.0 mg/kg/d in children, increasing the dose slowly until the hypertension is considered to be under control. One center prefers to use calcium channel blockers for preoperative preparation of children, with additional selective  $\alpha$ -adrenergic antagonists if necessary.<sup>26</sup>

DIAGNOSIS

The definitive diagnosis of pheochromocytoma rests primarily on showing excess, inappropriate production of catecholamines.<sup>27</sup> Fig 1 shows the synthesis and metabolism of catecholamines. Biochemical testing can establish the diagnosis in >95% of patients.<sup>6</sup> Measurements of plasma and urinary catecholamines and urinary total metanephrines seem to have the highest sensitivity, and urinary vanillylmandelic acid has the lowest sensitivity.<sup>6</sup> Measurements of plasma levels of normetanephrine and metanephrine have higher sensitivity than other biochemical tests for diagnosis of pheochromocytoma<sup>14</sup> and are useful in screening for pheochromocytomas in patients with a familial predisposition to these tumors.<sup>28</sup>

Tumor Localization

Pheochromocytomas can be identified and localized with nearly 100% sensitivity by properly choosing from the wide array of laboratory diagnostic and imaging tests.<sup>29</sup> Computed tomography (CT) and magnetic resonance imaging (MRI) provide accurate and consistent identification of most pheochromocytomas.<sup>11</sup> CT has good sensitivity (93% to 100%) for detecting adrenal pheochromocytoma, but sensitivity decreases to 90% for extra-adrenal pheochromocytomas (paragangliomas). MRI has equal or lower sensitivity for detecting adrenal pheochromocytomas but is superior for detecting extra-adrenal tumors. MRI may be preferable for detection of juxtacardiac and juxtavascular pheochromocytoma.<sup>14,30,31</sup> In pregnant patients, MRI may be the desirable procedure because it causes no harm to the fetus.<sup>6,31,32</sup>

Metaiodobenzylguanidine (MIBG) scanning offers excellent specificity (95% to 100%) and is helpful in diagnosing extra-adrenal tumors. MIBG is concentrated by the tumor's avid uptake of precursor amines; however, scanning requires 24 to 48 hours. Continuous rotation or spiral CT is helpful in detecting small thoracic tumors. Positron emission tomography with 6-(<sup>18</sup>F) fluorodopamine as the tracer can help locate the tumor in a patient with positive biochemical tests but negative conventional imaging studies.<sup>14</sup>

PREOPERATIVE MANAGEMENT

Patients with pheochromocytoma often have cardiovascular sequelae that require preoperative evaluation. Antihypertensive

medications are useful preoperative adjuvants to improve cardiac dysfunction and increase intravascular volume (Table 1).

Cardiac Evaluation

The functional capabilities of the cardiovascular system should be elicited by clinical history and, if indicated, diagnostic tests.<sup>1</sup> The most common effect of pheochromocytoma on the heart is the development of a hypertrophic cardiomyopathy caused by chronic norepinephrine-induced hypertension.<sup>11,33,34</sup> Dilated cardiomyopathy is much rarer<sup>33</sup> and may be associated with ventricular failure. It is not clear whether the ventricular failure results from  $\alpha$ - or  $\beta$ -adrenergic receptor activation,<sup>11</sup> direct cardiotoxic effects of catecholamines on the myocardium, or indirect effects of severe hypertension on the heart.<sup>35</sup> Histologically, myofibrillar degeneration with interstitial infiltration by mononucleocytes and resultant fibrosis and calcification are seen.<sup>11</sup> This cardiomyopathy resolved within 1 week after surgical removal of an acute-onset, highly functional pheochromocytoma.<sup>35</sup> In general, the cardiac dysfunction often improves after several weeks of  $\alpha$ -adrenergic blockade.<sup>1,33,36-38</sup>

Echocardiography is valuable in detecting dysfunction, evaluating improvement after  $\alpha$ -adrenergic blockade, and determining the optimal timing of surgery.<sup>1</sup> An echocardiogram should be done regardless of blood pressure levels to evaluate for the presence of dilated cardiomyopathy.<sup>6</sup> Most patients with pheochromocytoma (80%) have normal left ventricular mass. Plasma catecholamines are not the sole factor influencing the development of left ventricular hypertrophy in hypertension. It is possible that other factors, such as duration of hypertension, blood pressure level during normal activity, volume load pumped by the heart, and heredity, are important in the development of left ventricular hypertrophy.<sup>39</sup>

Pathologic findings on electrocardiograms are common in patients with pheochromocytoma, and significant improvements generally occur after surgery. Pathologic findings include high QRS amplitudes, abnormal R wave, ST-segment changes, and T-wave changes, all indicating myocardial hypertrophy, and prolongation of the Q-T<sub>c</sub> interval. Decreased QRS voltage with phenoxybenzamine therapy has been found in patients with sustained hypertension. Surgical resection of a pheochromocytoma results in normalization of QRS amplitudes and Q-T<sub>c</sub> intervals in most patients.<sup>40</sup>  $\alpha$ -Adrenergic stimulation prolongs the action potential. Prolongation of the Q-T interval as a result of pheochromocytoma has been described,<sup>41,42</sup> with normalization of the interval on resection of the tumor<sup>42</sup> or initiation of phenoxybenzamine.<sup>41</sup>

*Cardiac Pheochromocytoma Considerations.* Cardiac pheochromocytomas can be densely adherent to the myocardium, and resection is associated with significant morbidity and mortality. In a series of 25 patients, 5 (20%) died intraoperatively from hemorrhage; 1 (4%) died postoperatively from sepsis; 3 (12%) sustained myocardial infarction; 1 (4%) required a mitral valve replacement; and 3 (12%) had incomplete resections, 2 of whom subsequently developed metastatic disease and died. One patient received an orthotopic heart transplantation.<sup>19</sup>

Three tumor locations portend poor prognosis for resection: (1) atrioventricular groove with possible distortion of the mitral valve apparatus, (2) direct coronary involvement, and (3) extension into the left ventricle. Resection in these locations with

Table 1. Preoperative Anesthetic Considerations

Evaluate patient's overall health
Assess effectiveness of $\alpha_1$ -adrenergic blockade
Assess presence of cardiac dysfunction
Reassure patient

an adequate margin entails high surgical mortality secondary to exsanguination and myocardial infarction. Cardiac transplantation may be the optimal means of management for tumors in these locations if distant metastatic disease is excluded.<sup>19</sup> Coronary angiography should be performed before attempted resection of intrapericardial tumors for operative planning and to forewarn of the possible need for coronary resection and bypass.<sup>21</sup> Intraoperative transesophageal echocardiography can delineate the association of these tumors with the cardiac anatomy and can help guide surgical decision making.<sup>43</sup> Total circulatory arrest may be required to allow tumor excision in what otherwise would be a bloody field.<sup>21</sup>

### *Antihypertensive Medications*

Preoperative antihypertensive therapy is useful in patients with sustained or paroxysmal hypertension.<sup>2,40,44-46</sup> Perioperative mortality associated with pheochromocytoma resection decreased from 13% to 45% to 0% to 3% when  $\alpha$ -adrenergic blockade was introduced as preoperative therapy and when it was recognized that these patients often had hypovolemia preoperatively.<sup>47</sup>

The perioperative course is believed to be smoother with adequate preoperative preparation.<sup>23,48</sup> Preoperative  $\alpha$ -adrenergic blockade before pheochromocytoma resection, although commonly performed and generally recommended,<sup>47-51</sup> is not universally accepted as absolutely necessary to successful perioperative outcomes. Boutros et al<sup>44</sup> at the Cleveland Clinic noted that 0 of 29 patients in their series who did not receive preoperative  $\alpha$ -adrenergic blockade died, experienced a cerebrovascular accident, or had clinical manifestations of myocardial infarction. They concluded that advances in anesthetic and monitoring techniques and the availability of fast-acting drugs capable of correcting sudden hemodynamic changes have eliminated the need for preoperative  $\alpha$ -adrenergic blockade in preparing patients for pheochromocytoma resection. Conversely, in another series, 2 of 7 patients who received no preoperative  $\alpha$ -adrenergic blockade before pheochromocytoma resection died after a hypertensive crisis.<sup>45</sup> The low incidence of pheochromocytomas (1.5 to 2.0:100,000)<sup>52</sup> will likely preclude large, randomized, controlled trials to determine whether preoperative preparation is crucial.

**Phenoxybenzamine.** Phenoxybenzamine has been considered the drug of choice to control blood pressure alterations and associated symptoms.<sup>10</sup> Phenoxybenzamine blocks  $\alpha$ -adrenergic receptors noncompetitively and makes it difficult for released catecholamines to have a physiologic effect. It also permits intravascular volume expansion.<sup>10</sup> Its half-life is >24 hours.<sup>2</sup>

The routine use of phenoxybenzamine is controversial because the expansion of intravascular volume with  $\alpha$ -blocking agents takes 2 to 3 weeks.<sup>10</sup> Significant elevations of blood pressure still occur intraoperatively, especially during tumor manipulation, despite preoperative  $\alpha$ -blockade.<sup>9-11</sup> Orthostatic hypotension and reflex tachycardia occur, the latter secondary to inhibition of presynaptic  $\alpha_2$ -receptors at postganglionic neurons, resulting in increased release of norepinephrine.<sup>10</sup>  $\alpha$ -Adrenergic blockade may also contribute to the hypotensive state that follows removal of the tumor and may obscure the drop in blood pressure that signals the operative team that the tumor

has been completely removed.<sup>10</sup> The effects of phenoxybenzamine dissipate over approximately 36 hours, and large volumes of intravenous fluids are often required in the postoperative period.<sup>53</sup> Patients are often somnolent in the first 24 hours after surgery, which may be due to persistent central  $\alpha_2$ -adrenergic blockade.<sup>11</sup>

Preoperative  $\alpha$ -adrenergic blockade is usually performed on outpatients. The initial dose of phenoxybenzamine is 10 mg by mouth twice daily, combined with noninvasive monitoring of arterial pressure in the supine and standing positions. The dose is increased by 10-mg increments daily until stabilization of arterial pressure and reduction in symptoms have been achieved.<sup>2</sup> In 1 series, the average dose required was 44 mg/d (range, 10 to 240 mg/d),<sup>9</sup> and most patients required 10 to 14 days of therapy before surgery.<sup>47</sup> Patients can usually be safely prepared for surgery on an outpatient basis.<sup>54</sup> There is no evidence that preoperative phenoxybenzamine therapy for  $\geq 14$  days was more effective than 4 to 7 days of treatment in terms of the effect on intraoperative blood pressure, pulse rate, and cardiac arrhythmias.<sup>55,56</sup>

**Selective  $\alpha_1$ -Antagonists.** Selective competitive  $\alpha_1$ -adrenergic antagonists offer several potential advantages compared with phenoxybenzamine: They do not produce reflex tachycardia, they have a shorter duration of action and can be adjusted rapidly before surgery, and the duration of postoperative hypotension should be decreased.<sup>10</sup> Preoperative  $\beta$ -adrenoceptor antagonists are rendered unnecessary unless the patient has an epinephrine-secreting tumor because  $\alpha_2$ -adrenergic receptors (which regulate norepinephrine release at cardiac adrenergic nerve endings) are not antagonized. Intraoperatively, supplementary  $\alpha$ -adrenergic and  $\beta$ -adrenergic blockade may still be necessary, however, during surgical manipulation of the tumor.<sup>11</sup> Doxazosin has a long duration of action, allowing once-daily dosing, and may have a near-ideal profile for the preoperative management of patients with pheochromocytoma.<sup>11</sup> The dose of doxazosin is 1 to 16 mg as a single oral dose taken daily.<sup>10</sup> Prys-Roberts<sup>11</sup> used doxazosin preoperatively in 20 patients with pheochromocytoma or paraganglioma in doses of 2 to 8 mg daily and noted that preoperative arterial pressure was controlled at least as well as with phenoxybenzamine. Doxazosin was inadequate monotherapy in 1 patient, however; supplementation with octreotide decreased the frequency of paroxysmal hypertensive episodes in this patient.<sup>57</sup>

Selective competitive  $\alpha_1$ -adrenergic blockade with prazosin and terazosin may be considered, but both agents require more frequent dosing. Prazosin has a short elimination half-life (2 to 3 hours), and blood concentrations may decrease to ineffective levels at the time of surgery if the last dose was given on the previous night.<sup>11</sup> The initial dose of prazosin is 1.0 mg 3 to 4 times daily.<sup>10</sup> Terazosin is an alternative selective  $\alpha_1$ -adrenergic antagonist that has a shorter half-life than doxazosin.<sup>11</sup> The initial dose of terazosin is 1 mg each night, with a maximal dose of 20 mg at night.

**Guidelines to Adequate  $\alpha$ -Adrenergic Blockade.** The following criteria for optimal preoperative condition are recommended by Roizen et al<sup>47</sup>: (1) No blood pressure reading >160/90 mmHg should be evident for 24 hours before surgery; (2) orthostatic hypotension, with readings >80/45 mmHg, should be present; (3) the electrocardiogram should be free of



ST-T changes for at least 1 week; and (4) the patient should have no more than 1 premature ventricular contraction every 5 minutes. Poor perioperative outcomes have occurred in patients who did not meet these criteria before pheochromocytoma resection.<sup>36</sup>

**Calcium Channel Antagonists.** Calcium channel antagonists may be safely used in patients who are normotensive but who have occasional episodes of paroxysmal hypertension because they do not produce orthostatic hypotension or overshoot hypotension. Calcium channel antagonists may prevent catecholamine-induced coronary vasospasm and myocarditis. They likely reduce arterial pressure by inhibiting norepinephrine-mediated transmembrane calcium influx in vascular smooth muscle and not by decreasing catecholamine synthesis in tumors.<sup>10</sup> The usual effective dose of nifedipine is 30 to 90 mg/d.<sup>10</sup> Oral diltiazem (240 mg/d) has been used preoperatively with poor results intraoperatively.<sup>58</sup> Nicardipine infusion has been used intraoperatively with rapid control of hemodynamic changes.<sup>10,59,60</sup> Recommended infusions in adults begin at 5 mg/h, increasing by 2.5 mg/h every 5 minutes to a maximum of 15 mg/h. As with all intravenous antihypertensives, the dose should be titrated to the desired blood pressure response.

**$\beta$ -Adrenergic Antagonists.** Pretreatment with a  $\beta$ -adrenergic blocking agent is not routinely necessary in the absence of arrhythmias.<sup>51</sup>  $\beta$ -Adrenergic blockade is contraindicated in the absence of established  $\alpha_1$ -blockade because circulating catecholamines would affect vasoconstriction without opposition by the vasodilating  $\beta_2$ -receptors. The resultant hypertension may lead to pulmonary edema, which could be aggravated by the negative inotropic effect of the  $\beta$ -blockade.<sup>10,61</sup> Labetalol, an  $\alpha$ -adrenergic and  $\beta$ -adrenergic blocker, has been used, starting with 100 mg orally 4 times daily, advancing gradually to 800 to 1,600 mg/d. It has precipitated hypertensive crises, however.<sup>10</sup>

The efficacy of  $\beta$ -blockade in preventing intraoperative arrhythmias has been questioned.<sup>62</sup> Decreased left ventricular performance can occur during tumor manipulation, and this may be aggravated by  $\beta$ -adrenergic blockade.  $\beta$ -Adrenergic blockade should be avoided in patients with catecholamine-induced cardiomyopathy, which can increase a patient's vulnerability to developing intractable hypotension, bradycardia, and asystolic cardiac arrest.<sup>36</sup>

**$\alpha$ -Methyl-para-tyrosine.**  $\alpha$ -Methyl-para-tyrosine competitively inhibits tyrosine hydroxylase, which is the rate-limiting step in catecholamine biosynthesis. It reduces tumor stores of catecholamines, decreasing the ability of the tumor to react to stimulation.<sup>14</sup> It may be useful for patients with congestive heart failure in whom  $\alpha$ -adrenergic blockade leads to tachycardia or  $\beta$ -adrenergic blockade diminishes cardiac performance. The oral dose is 0.5 g/d up to a maximum of 4 g/d.<sup>52</sup> It is associated with a high incidence of adverse side effects, however.<sup>11</sup> Steinsapir et al<sup>45</sup> found that a combination of  $\alpha$ -metyrosine and  $\alpha$ -adrenergic blockade resulted in better blood pressure control and less need for use of antihypertensive medication or pressors during surgery compared with single-agent adrenergic blockade.

**Angiotensin-Converting Enzyme Inhibitors.** The ability of angiotensin-converting enzyme inhibitors to reverse left ventricular hypertrophy is not valuable in the preoperative man-

**Table 2. Intraoperative Anesthetic Considerations**

Administer an anxiolytic
Place an intra-arterial catheter before induction
Place an intravenous catheter for antihypertensive administration (eg, sodium nitroprusside or nicardipine) before induction
Place a central venous catheter for intravascular volume monitoring
Treat hemodynamic fluctuations with antihypertensives and $\beta$ -adrenergic antagonists
Monitor for hypotension and hypoglycemia after tumor isolation

agement of most pheochromocytomas. The goal is removal of the hypertensive stimulus (norepinephrine), and the heart usually reverts to normal after surgery.<sup>11</sup>

### Preoperative Sedation

Preoperative sedation and assurance by the anesthesiologist may decrease anxiety and prevent marked hemodynamic fluctuations in the immediate preoperative period.<sup>1</sup> No preoperative anxiolytics have proved superior to others.

## INTRAOPERATIVE MANAGEMENT

Close, collegial communication is crucial to the success of intraoperative management of patients undergoing pheochromocytoma resection. Preoperative discussion of anticipated problems and the ability to perform as a team alleviate many of the potential concerns and problems that can arise intraoperatively (Table 2).

### Monitoring Systems and Intravascular Cannulae

An intra-arterial catheter for pressure monitoring is essential and should be placed before the induction of anesthesia. This catheter allows immediate identification of hemodynamic fluctuations and rapid pharmacologic intervention.<sup>1</sup> In addition to an intravenous catheter for administration of medications and fluids, a second intravenous catheter, preferably close to the central venous system, may be used exclusively to administer sodium nitroprusside. Sodium nitroprusside is a rapid-acting and easily controlled vasodilator. A low dose of sodium nitroprusside may be started before induction of anesthesia, and the infusion may be rapidly altered during induction and throughout the procedure in response to hemodynamic fluctuations.<sup>1</sup> Central venous catheter placement for infusion and monitoring is commonly used and recommended.<sup>9,11,17</sup>

Urine production by catheterization of the bladder, continuous electrocardiogram,<sup>2</sup> pulse oximeter, capnograph, and temperature should be monitored.<sup>63</sup> Electroencephalography and somatosensory evoked potentials have been used intraoperatively in a patient with pheochromocytoma and a recent cerebral infarction.<sup>64</sup>

Measurement of pulmonary capillary wedge pressure (PCWP) and cardiac output (CO) may be helpful because these patients may exhibit a discrepancy between right-sided and left-sided filling pressures, particularly during manipulation of the tumor or during rapid infusion of fluid. These findings have been noted in patients without any apparent cardiac dysfunction before surgery.<sup>2,65</sup> In 1 report, ventricular dysfunction was

transient, and management was not influenced by PCWP and CO data; these data are crucial only in certain patients, such as those with preoperative cardiovascular compromise.<sup>2</sup>

PCWP should be monitored in the presence of heart disease.<sup>17</sup> Prys-Roberts<sup>11</sup> found, however, that there was a need for pulmonary artery catheter use in only 1 of 50 operations for pheochromocytoma. Only 7% of patients undergoing pheochromocytoma or paraganglioma resection at the Mayo Clinic between 1983 and 1996 underwent pulmonary artery catheter placement and monitoring intraoperatively.<sup>9</sup> Nonetheless, others have noted that a severe hypertensive and tachycardic crisis perioperatively may decrease left ventricular compliance, which is not always detected by central venous pressure measurement.<sup>50</sup> Potential problems with vascular capacity versus circulating blood volume, especially after removal of the tumor, may make the availability of PCWP and CO measurements useful.<sup>50</sup>

### General Anesthesia

General anesthesia is the most common technique chosen. Almost all anesthetic agents have been used at some time with success.<sup>2</sup> The depth of anesthesia is generally more important than the specific agent because it can inhibit adrenergic and cardiovascular responses.<sup>2</sup>

**Inhalation Agents.** Sevoflurane has become the agent of choice for maintenance of anesthesia in patients undergoing pheochromocytoma resection at the Mayo Clinic. Isoflurane and enflurane also have been safely used in pheochromocytoma resection.<sup>9,66</sup> Enflurane has a more negative inotropic cardiac effect than isoflurane and is used less frequently. Halothane results in severe arrhythmias,<sup>2</sup> likely owing to the sensitization of the myocardium to the effects of catecholamines by decreasing the arrhythmogenic threshold doses for epinephrine.<sup>67</sup> Desflurane causes significant sympathetic stimulation and may not be the best volatile agent for pheochromocytoma resection.<sup>68</sup> There are no contraindications to the use of nitrous oxide in patients with pheochromocytoma.<sup>69</sup>

**Intravenous Agents.** Induction with thiopental is common<sup>2</sup> and has produced excellent results.<sup>70</sup> Propofol has also been safely used.<sup>71</sup> Etomidate has been recommended as a suitable agent with superior cardiovascular stability.<sup>69</sup> Agents that cause an indirect increase in catecholamines levels, such as ketamine and ephedrine, should be avoided.<sup>72</sup> Morphine causes histamine release, which is a known trigger of pheochromocytoma crisis.<sup>50</sup> Meperidine causes sympathetic stimulation and should be avoided.<sup>73</sup> Droperidol administration has been associated with extreme hypertension.<sup>74,75</sup> All of the intravenous agents can be safely used, however, as long as their potential side effects are considered. Slow administration of these drugs usually prevents or attenuates these effects.

**Neuromuscular Blockers.** The type of muscle relaxant used is likely of secondary importance. Succinylcholine may cause mechanical stimulation of the tumor by fasciculations<sup>2,69</sup> and may stimulate autonomic ganglia, resulting in increased catecholamines and cardiac arrhythmias.<sup>76</sup> It was used successfully, however, in 61% of all patients undergoing pheochromocytoma resection at the Mayo Clinic between 1983 and 1996.<sup>9</sup> Pancuronium has been used in approximately 80 patients without any problems.<sup>2</sup> Pancuronium has been implicated in caus-

ing a severe pressor response in 1 patient with pheochromocytoma,<sup>77</sup> however, and has a vagolytic effect that can result in tachycardia.<sup>50</sup> Atracurium, which may cause release of histamine, has been associated with severe arterial hypertension, ventricular arrhythmias, and elevation of plasma catecholamine levels.<sup>78</sup> Tubocurarine has been shown to release histamine, and subsequent catecholamine release from a pheochromocytoma by tubocurarine has been associated with at least 1 intraoperative fatality.<sup>79</sup> Gallamine has a vagolytic effect, and curare can cause histamine release; both should be avoided if possible.<sup>50</sup> Vecuronium has little or no autonomic effects and does not release histamine. It produced minimal changes in arterial pressure and plasma catecholamine levels in 3 patients<sup>80</sup> and may eventually be confirmed as the drug of choice.<sup>78</sup> Vecuronium was the most commonly used nondepolarizing neuromuscular blocker in patients undergoing pheochromocytoma resection at the Mayo Clinic between 1983 and 1996.<sup>9</sup>

### Regional Anesthesia

Spinal anesthesia<sup>81</sup> and epidural analgesia<sup>24,36,70,81,82</sup> occasionally have been used with satisfactory results. The use of a combined regional technique with general anesthesia must be balanced against the risk of hypertension during its placement because sympathetic blockade does nothing to protect against catecholamine release during tumor manipulation.<sup>73,83</sup>

### Hypertension and Arrhythmias

Hypertension during pheochromocytoma resection seems to have 2 distinct origins. First, noxious stimuli, such as tracheal intubation, skin incision, and abdominal exploration, are not consistently accompanied by increased tumor secretion of catecholamines<sup>2</sup>, but more likely cause catecholamine release from excessive stores in adrenergic nerve endings.<sup>84</sup> Deepening the level of anesthesia may block the cardiovascular response to noxious stimuli.<sup>2,40</sup>

Second, palpation of the tumor produces a more severe hypertensive response, which is associated with marked increases in plasma norepinephrine and epinephrine concentrations<sup>85</sup> and increased systemic vascular resistance, PCWP, and occasionally decreased CO, suggesting left ventricular dysfunction.<sup>2</sup> Hypertensive responses caused by tumor manipulation can be prevented only by careful surgical handling of tumor tissue. They are best treated with vasodilators.<sup>40</sup>

Lidocaine and  $\beta$ -adrenergic blocking agents have been used to treat arrhythmias. Propranolol has a duration of action of 30 to 45 minutes and may persist after removal of the tumor.<sup>2</sup> Lidocaine's short duration of action and absence of negative inotropic properties in a dose of 1 mg/kg are advantages, and lidocaine has been effective.<sup>8</sup>

**Direct Vasodilators: Nitroprusside and Nitroglycerin.** Hypertensive crises may be managed with sodium nitroprusside. Sodium nitroprusside should be used in patients with pheochromocytoma and complicating acute myocardial infarction or congestive heart failure to obtain a gradual reduction of arterial blood pressure. It decreases preload and afterload.<sup>10</sup> Its onset is immediate, and recovery occurs in 1 to 2 minutes.<sup>2</sup> At higher doses, toxic metabolites, such as cyanide and thiocyanate, are a

**Table 3. Adrenal Steroid Replacement in Bilateral Adrenalectomy**

Day of operation	Methylprednisolone, 40 mg IV every 8 h for 3 doses
Postoperative day 1	Methylprednisolone, 20 mg IV every 8 h for 3 doses
Postoperative day 2	Methylprednisolone, 10 mg IV every 8 h for 3 doses
Maintenance	Prednisone, 5 mg orally each morning and 2.5 mg each evening, and fludrocortisone, 0.1 mg each morning

Abbreviation: IV, intravenously.

concern.<sup>86</sup> Intravenous nitroglycerin is a rapid-acting agent that mainly affects capacitance vessels.<sup>2</sup> Similar to nitroprusside, its onset and duration are rapid.<sup>86</sup>

**$\alpha$ -Adrenergic Antagonist.** Phentolamine is a competitive  $\alpha_1$ -adrenergic and weak  $\alpha_2$ -adrenergic receptor antagonist that can be given intravenously as an infusion or as incremental doses of 1 to 2 mg. In patients receiving intraoperative  $\beta$ -adrenergic blockade, tachycardia attributable to the phentolamine is not typically seen.<sup>11</sup>

**$\beta$ -Adrenergic Antagonists.**  $\beta$ -Adrenergic antagonists can help control tachycardia or tachyarrhythmias. Esmolol is a selective  $\beta_1$ -antagonist with a short duration of action.<sup>10</sup> Esmolol has hemodynamic effects that may be uniquely suited for the intraoperative management of pheochromocytoma.<sup>87</sup> There is little evidence that residual  $\beta$ -adrenergic blockade by longer acting drugs is a disadvantage.<sup>11</sup>

**Calcium Channel Blockers.** Advantages of calcium channel blockers over sodium nitroprusside include little reduction in preload, less potential for overshoot hypotension, no rebound hypertension, less increase in heart rate, and absence of cyanide toxicity.<sup>73</sup> Nicardipine is a calcium channel blocker with a potent vasodilating action.<sup>59</sup> Although it has been shown to inhibit catecholamine release from adrenal medullary tissue *in vitro*,<sup>88</sup> several studies have shown that it does not attenuate the release of catecholamines *in vivo*.<sup>59,89-92</sup> Nicardipine does not prevent marked intraoperative increase of free plasma catecholamine levels in patients undergoing pheochromocytoma resection, despite preoperative preparation with oral nicardipine, 60 to 120 mg/24 h for 1 to 8 days, and intraoperative nicardipine, 2.5 to 7.5  $\mu$ g/kg/min.<sup>59</sup> Intravenous nicardipine has an onset of 1 to 5 minutes but has a duration of 3 to 6 hours.<sup>86</sup>

**Dopamine-1 Receptor Agonist.** Fenoldopam causes peripheral vasodilation by selective stimulation of dopamine-1 receptors and increases renal blood flow. Although increased renal blood flow may be beneficial in patients with renal impairment, drug-induced diuresis is undesirable during pheochromocytoma resection.<sup>86</sup>

### Hypotension

Persistence of hypotension might be caused by inadequate intravascular volume, residual effects of preoperative  $\alpha$ -adrenergic blockade, sudden increases in venous capacitance, and hemorrhage. Fluids should be administered first because these patients require large amounts of volume after tumor resection.<sup>10</sup> The volume of infused fluids in addition to compensation for blood loss in 1 study ranged from 500 to 3,000 mL (mean, 1,100  $\pm$  500 mL) before resection and was 1,200  $\pm$  200 mL (mean  $\pm$  SD) after resection.<sup>8</sup> Control of hypotension by fluid replacement is believed to be the factor responsible for reduction in operative mortality, rather than the use of cat-

echolamines after tumor resection.<sup>2</sup> Pressor agents are generally ineffective in the setting of persistent hypovolemia.<sup>10</sup> If vasopressors are used, norepinephrine, phenylephrine, and dopamine have all been recommended.<sup>2,93</sup>

### Hyperglycemia

Hyperglycemia may occur preoperatively and intraoperatively as a result of catecholamine excess.<sup>6,10</sup> Insulin release and action are antagonized by an  $\alpha_2$ -adrenergic-mediated mechanism. Increased glycogenolysis and free fatty acid mobilization also contribute to preoperative hyperglycemia in approximately 60% of patients. This hyperglycemia rarely requires treatment with insulin and resolves after pheochromocytoma resection.<sup>94</sup> Hypoglycemia may occur after tumor excision because of rebound hyperinsulinism as the inhibitory effect of norepinephrine on insulin secretion is eliminated.<sup>6,10</sup> Slow emergence from anesthesia or lethargy after extubation may result.  $\beta$ -Adrenergic blockers can impair recovery from hypoglycemia and mask clinical symptoms of hypoglycemia.<sup>10</sup>

### Perioperative Steroid Replacement in Bilateral Adrenalectomy

Patients with bilateral adrenal disease require steroid replacement (Table 3). When oral intake resumes, adult patients should receive maintenance prednisone, 5.0 mg each morning and 2.5 mg each evening, along with fludrocortisone, 0.1 mg each morning.<sup>1</sup>

### Surgical Approach

Successful surgery requires the cooperation of the surgeon, the anesthesiologist, and the endocrinologist. Surgery for pheochromocytoma is technically demanding and preferably is done in centers that have experience with this disease.<sup>17</sup>

**Anterior or Transabdominal Approach.** The anterior or transabdominal approach is used more frequently in patients with the familial form of the tumor because of the higher incidence of bilateral adrenal gland involvement.<sup>3</sup> Large masses and masses that may be malignant generally should be resected using an anterior approach to allow adequate exploration and safe resection.<sup>95</sup> The patient is placed supine, with 1 or both arms tucked at the side.<sup>1</sup> The flank may be elevated 30° on a pillow. The table is flexed, and the space between the costal margin and the anterior superior iliac spine on the side to be removed is widened.<sup>95</sup>

**Other Approaches.** The posterior approach is not recommended for pheochromocytoma resection because a great deal of tumor manipulation and pressure on the adrenal gland are necessary.<sup>1</sup> The patient is placed prone on the operating room

table and flexed at the waist.<sup>95</sup> The thoracoabdominal approach is reserved almost exclusively for large malignant pheochromocytomas. The patient's side to be operated on is elevated 45° from the operating table, and the arm on that side is placed in a sling above the patient's head. The incision is initially epigastric, with ipsilateral extension if necessary. The chest also may be entered through the 11th interspace without resection of any ribs.<sup>1</sup> Most intrathoracic pheochromocytomas occur in the posterior mediastinum, but some are associated with the heart. Resection of lesions that invade adjacent myocardium is associated with significant mortality and incomplete resection of the neoplasm. Cardiac transplantation should be available as an option before embarking on resection, and it should be performed if indicated by intraoperative findings.<sup>19</sup>

**Laparoscopic Adrenalectomy.** Laparoscopic adrenalectomy for pheochromocytoma produces less postoperative pain, shortened hospital stay and convalescent period,<sup>96-98</sup> and fewer incisional complications.<sup>97</sup> The laparoscopic approach to adrenalectomy is considered the procedure of choice<sup>99,100</sup> except in the case of invasive carcinoma or masses >15 cm.<sup>101</sup>

Carbon dioxide pneumoperitoneum can induce catecholamine release by a pheochromocytoma, and yet it is often well tolerated.<sup>60,102,103</sup> Laparoscopic adrenalectomy for pheochromocytoma has been associated with a greater increase in mean arterial pressure, central venous pressure, and PCWP before tumor excision than in patients undergoing the open abdominal approach. In 1 report, the cardiac index and left ventricular work index were not significantly changed.<sup>103</sup> Catecholamine levels in pheochromocytoma patients increased the most during tumor manipulation in conventional transabdominal adrenalectomy and in laparoscopic adrenalectomy, but cardiovascular instability was associated only with conventional transabdominal adrenalectomy.<sup>46</sup>

Positioning for laparoscopic surgery involves placing the patient in the full lateral position with the anticipated tumor site uppermost.<sup>11</sup> For a laparoscopic bilateral adrenalectomy, the left side may be performed first because it is thought that this operation is easier. After the left side is completed, the patient is repositioned and redraped with the right side up. For a laparoscopic transperitoneal approach, the table is flexed. A rolled sheet is positioned under the patient at the axilla and umbilicus. The operative side should be hyperextended until the flank musculature is slightly taut. The left arm is extended and suspended. Three to five trocars are used. When the lateral portion of the adrenal gland is exposed, the table is tilted to a head-up position.<sup>101</sup>

**Carotid Body Tumor and Paraganglioma Excision.** Carotid body tumors are paragangliomas that arise in the carotid body or, less commonly, in one of the adjacent nerves, such as the vagus. These tumors infrequently secrete active substances, but still should be excised because these tumors grow and become more difficult to remove. Also, a small proportion metastasize to the lymph nodes.<sup>104</sup>

Carotid body tumor resection is attempted in an avascular plane, avoiding the need for cross-clamping the carotid artery. There is the potential for major hemorrhage, however, because the tumors are highly vascular and invasive. With large and highly invasive tumors, it may be necessary to open or excise a part of the carotid artery and repair it with a graft, necessi-

tating carotid cross-clamping with or without an intraluminal shunt.<sup>4</sup> Postoperative complications include airway compromise owing to the development of a hematoma, tissue edema, and vocal cord paralysis. Disturbed baroreceptor function may present as fluctuating pulse and blood pressure. Cerebral ischemia can arise if a graft thromboses.<sup>4</sup>

**Cardiac Exposure.** The optimal surgical exposure is obtained with a transsternal midline thoracotomy.<sup>105</sup> Cardiopulmonary bypass and cardioplegia isolate the heart from the systemic circulation, decreasing the risk of systemic release of vasoactive compounds.<sup>106</sup>

## POSTOPERATIVE MANAGEMENT

Approximately 50% of patients remain hypertensive for a few days, likely related to elevated catecholamine stores in adrenergic nerve endings, which persist for 1 week after pheochromocytoma resection.<sup>2</sup> Persistent hypertension may represent fluid excess, return of autonomic reflexes, inadvertent ligation of a renal artery, or presence of residual tumor.<sup>107</sup>

Residual nonparoxysmal hypertension is found in 27% to 38% of patients after pheochromocytoma removal.<sup>14</sup> Familial hypertension and age were associated with persistence of hypertension.<sup>108</sup> Conversely, persistent hypotension may be due to loss of blood, alteration of vascular compliance, and residual effects of preoperative adrenergic blockade.<sup>107</sup> The most common serious postoperative complication after resection of cardiac pheochromocytoma is massive bleeding.<sup>109</sup>

Patients who have undergone bilateral removal of carotid bodies should have careful perioperative respiratory monitoring because severe respiratory insufficiency has been reported.<sup>5</sup> Postoperative blood glucose monitoring is recommended because hypoglycemia has been reported (Table 4).<sup>110,111</sup>

### Follow-Up Examination and Assay for Catecholamines

Evaluation of plasma metanephrine levels at 6 weeks and at 6 months after surgery is part of postoperative follow-up.<sup>14</sup> Recurrence has occurred 41 years after the initial surgical resection; lifelong follow-up is necessary.<sup>3</sup> Yearly follow-up is recommended in familial pheochromocytoma given the high rate of tumor recurrence,<sup>14,112</sup> and all family members should be screened.<sup>112</sup>

Nuclear DNA ploidy pattern is an important and independent prognostic variable for patients with pheochromocytoma and paraganglioma. Patients with DNA nondiploid tumors (DNA tetraploid, DNA aneuploid) have a more malignant course than patients with DNA diploid tumors.<sup>39</sup> Large tumor size and local tumor extension at the time of surgery were the most significant prognostic variables in predicting a future malignant course.<sup>113</sup> About 10% of patients with adrenal pheochromocytoma<sup>113</sup> and 10% to 40% with paraganglioma are at risk of subsequent disease progression.<sup>114,115</sup>

**Table 4. Postoperative Considerations**

Assess and manage decreased intravascular volume
Anticipate residual $\alpha_1$ -adrenergic blockade
Monitor for hypoglycemia



### Long-Term Medical Management

Malignant pheochromocytomas (defined not by histologic appearance, but rather by the presence of metastases)<sup>3</sup> often do not cause severe hypertension or symptoms. These tumors may spread locally or metastasize to the lungs, bones, and soft tissue. Surgical debulking may be performed to relieve symptoms and control hypertension. Antihypertensive medications ( $\alpha$ -adrenergic and  $\beta$ -adrenergic antagonists and calcium channel antagonists) have been used with success. Tyrosine hydroxylase decreases the production of catecholamines but has serious side effects, such as extrapyramidal signs, diarrhea, anxiety, and crystalluria. Radiation and chemotherapy are used to treat intractable pain or symptoms of catecholamine excess that cannot be pharmacologically controlled.<sup>10</sup> Besides surgical therapy, no other forms of therapy are curative.<sup>3</sup>

The treatment of hereditary forms of pheochromocytoma is controversial. Treatment has included unilateral adrenalectomy for functional tumors, prophylactic bilateral adrenalectomy, or follow-up observation of small nonfunctional pheochromocytomas.<sup>14</sup>

### SUMMARY

Pheochromocytomas are catecholamine-secreting tumors. They present with hypertension, headache, hyperhidrosis, and palpitations. Surgical resection is the treatment of choice. Most perioperative morbidity involves the cardiovascular system. Echocardiograms are useful regardless of the blood pressure to evaluate ventricular function. Preoperative hypertrophic or dilated cardiac pathology often improves after surgical removal

of the pheochromocytoma or after several weeks of  $\alpha$ -adrenergic blockade.

Preoperative control of hypertension (usually with  $\alpha$ -adrenergic blockade) is probably important, although modern anesthetic care with central infusion of vasodilators and other antihypertensive drugs allows satisfactory perioperative outcomes. Rhythm abnormalities are rarely life-threatening and perioperative  $\beta$ -blockade, although stabilizing cardiac rhythm, may exacerbate ventricular dysfunction.

General anesthesia is the preferred anesthetic technique. The skill with which it is administered is probably more important than any individual agent. Halothane sensitizes the heart to catecholamines, and desflurane and ketamine cause some sympathetic stimulation; all of these are best avoided. Agents that release histamine (tubocurarine, atracurium in high doses, gallamine) have been reported to cause massive catecholamine release from these tumors and should not be used. Wide swings in blood pressure are best treated with central venous titrated infusions of nitrovasodilators or nicardipine.

Most patients with pheochromocytoma present with intravascular volume depletion, and appropriate perioperative fluid should be given. Hyperglycemia can occur before tumor removal as a result of catecholamine excess, and rebound hyperinsulinemia may cause postoperative hypoglycemia. If bilateral adrenalectomies are performed, steroid replacement therapy should begin intraoperatively. Postoperative hypotension may be due to residual  $\alpha$ -adrenergic blockade, hypovolemia, or alteration of vascular compliance because of the chronic catecholamine exposure. Knowledge of these principles should allow logical clinical decisions by anesthesiologists providing care for patients with pheochromocytoma.

### REFERENCES

- Warner MA, van Heerden JA: Pheochromocytoma: Anesthetic and surgical management employed at the Mayo Clinic, in Manger WM, Gifford Jr RW (eds) *Clinical and Experimental Pheochromocytoma*. Cambridge, MA, Blackwell Science, 1996, pp 388-407
- Desmots JM, Marty J: Anaesthetic management of patients with pheochromocytoma. *Br J Anaesth* 56:781-789, 1984
- Werbel SS, Ober KP: Pheochromocytoma: Update on diagnosis, localization, and management. *Med Clin North Am* 79:131-153, 1995
- Duncan LA: Anaesthesia for carotid artery disease, in Bannister J, Wildsmith JAW (eds): *Anaesthesia for Vascular Surgery*. London, Arnold, 2000, pp 251-266
- Connolly RA, Baker AB: Excision of bilateral carotid body tumours. *Anaesth Intensive Care* 23:342-345, 1995
- Bravo EL: Evolving concepts in the pathophysiology, diagnosis, and treatment of pheochromocytoma. *Endocr Rev* 15:356-368, 1994
- Remine WH: Current management of pheochromocytoma. *Ann Surg* 179:740-748, 1974
- Desmots JM, le Houelleur J, Remond P, et al: Anaesthetic management of patients with phaeochromocytoma: A review of 102 cases. *Br J Anaesth* 49:991-998, 1977
- Kinney MA, Warner ME, van Heerden JA, et al: Perianesthetic risks and outcomes of pheochromocytoma and paraganglioma resection. *Anesth Analg* 91:1118-1123, 2000
- Bravo EL: Pheochromocytoma. *Curr Ther Endocrinol Metab* 6:195-197, 1997
- Prys-Roberts C: Phaeochromocytoma—recent progress in its management. *Br J Anaesth* 85:44-57, 2000
- Allen GC, Rosenberg H: Phaeochromocytoma presenting as acute malignant hyperthermia—a diagnostic challenge. *Can J Anaesth* 37:593-595, 1990
- Newell KA, Prinz RA, Pickleman J, et al: Pheochromocytoma multisystem crisis: A surgical emergency. *Arch Surg* 123:956-959, 1988
- Pacak K, Linehan WM, Eisenhofer G, et al: Recent advances in genetics, diagnosis, localization, and treatment of pheochromocytoma. *Ann Intern Med* 134:315-329, 2001
- Walther MM, Keiser HR, Linehan WM: Pheochromocytoma: Evaluation, diagnosis, and treatment. *World J Urol* 17:35-39, 1999
- Eisenhofer G, Walther MM, Huynh TT, et al: Pheochromocytomas in von Hippel-Lindau syndrome and multiple endocrine neoplasia type 2 display distinct biochemical and clinical phenotypes. *J Clin Endocrinol Metab* 86:1999-2008, 2001
- Young JB, Landsberg L: Catecholamines and the adrenal medulla, in Wilson JD, Foster DW, Kronenberg HM, Larsen PR (eds): *Williams Textbook of Endocrinology*. Philadelphia, PA, Saunders, 1998, pp 705-728
- Pickering TG, Isom OW, Bergman GW, et al: Pheochromocytoma of the heart. *Am J Cardiol* 86:1288-1289, 2000
- Jeevanandam V, Oz MC, Shapiro B, et al: Surgical management of cardiac pheochromocytoma: Resection versus transplantation. *Ann Surg* 221:415-419, 1995
- Jebara VA, Uva MS, Farge A, et al: Cardiac pheochromocytomas. *Ann Thorac Surg* 53:356-361, 1992
- Vander Salm TJ: Unusual primary tumors of the heart. *Semin Thorac Cardiovasc Surg* 12:89-100, 2000

22. Tekin UN, Khan IA, Singh N, et al: A left atrial paraganglioma patient presenting with compressive dysphagia. *Can J Cardiol* 16:383-385, 2000
23. Vaughan Jr ED: The adrenals, in Walsh PC, Retik AB, Vaughan ED Jr, Wein AJ (eds): *Campbell's Urology*. Philadelphia, PA, Saunders, 1998, pp 2948-2972
24. Stonham J, Wakefield C: Pheochromocytoma in pregnancy. *Anaesthesia* 38:654-658, 1983
25. Hack HA: The perioperative management of children with pheochromocytoma. *Paediatr Anaesth* 10:463-476, 2000
26. Ross JH: Pheochromocytoma: Special considerations in children. *Urol Clin North Am* 27:393-402, 2000
27. Bravo EL: Plasma or urinary metanephrines for the diagnosis of pheochromocytoma? That is the question. *Ann Intern Med* 125:331-332, 1996
28. Eisenhofer G, Lenders JW, Linehan WM, et al: Plasma normetanephrine and metanephrine for detecting pheochromocytoma in von Hippel-Lindau disease and multiple endocrine neoplasia type 2. *N Engl J Med* 340:1872-1879, 1999
29. Witteles RM, Kaplan EL, Roizen MF: Sensitivity of diagnostic and localization tests for pheochromocytoma in clinical practice. *Arch Intern Med* 160:2521-2524, 2000
30. Lin JC, Palafox BA, Jackson HA, et al: Cardiac pheochromocytoma: Resection after diagnosis by 111-indium octreotide scan. *Ann Thorac Surg* 67:555-558, 1999
31. Hanna NN, Kenady DE: Advances in the management of adrenal tumors. *Curr Opin Oncol* 12:49-53, 2000
32. Sheps SG, Jiang NS, Klee GG, et al: Recent developments in the diagnosis and treatment of pheochromocytoma. *Mayo Clin Proc* 65:88-95, 1990
33. Quigg RJ, Om A: Reversal of severe cardiac systolic dysfunction caused by pheochromocytoma in a heart transplant candidate. *J Heart Lung Transplant* 13:525-532, 1994
34. Scully R, Mark E, McNeely W, et al: Case 15-1988. *N Engl J Med* 318:970-981, 1988
35. Perrier NA, van Heerden JA, Wilson DJ, et al: Malignant pheochromocytoma masquerading as acute pancreatitis—a rare but potentially lethal occurrence. *Mayo Clin Proc* 69:366-370, 1994
36. Shupak RC: Difficult anesthetic management during pheochromocytoma surgery. *J Clin Anesth* 11:247-250, 1999
37. Lam JB, Shub C, Sheps SG: Reversible dilatation of hypertrophied left ventricle in pheochromocytoma: Serial two-dimensional echocardiographic observations. *Am Heart J* 109:613-615, 1985
38. Nanda AS, Feldman A, Liang CS: Acute reversal of pheochromocytoma-induced catecholamine cardiomyopathy. *Clin Cardiol* 18:421-423, 1995
39. Fouad-Tarazi FM, Imamura M, Bravo EL, et al: Differences in left ventricular structural and functional changes between pheochromocytoma and essential hypertension: Role of elevated circulating catecholamines. *Am J Hypertens* 5:134-140, 1992
40. Marty J, Desmonts JM, Chalaux G, et al: Hypertensive responses during operation for pheochromocytoma: A study of plasma catecholamine and haemodynamic changes. *Eur J Anaesthesiol* 2:257-264, 1985
41. Viskin S, Fish R, Roth A, et al: Clinical problem-solving. QT or not QT? *N Engl J Med* 343:352-356, 2000
42. Stenstrom G, Swedberg K: QRS amplitudes, QTc intervals and ECG abnormalities in pheochromocytoma patients before, during and after treatment. *Acta Med Scand* 224:231-235, 1988
43. Mandak JS, Benoit CH, Starkey RH, et al: Echocardiography in the evaluation of cardiac pheochromocytoma. *Am Heart J* 132:1063-1066, 1996
44. Boutros AR, Bravo EL, Zanettin G, et al: Perioperative management of 63 patients with pheochromocytoma. *Cleve Clin J Med* 57:613-617, 1990
45. Steinsapir J, Carr AA, Prisant LM, et al: Metyrosine and pheochromocytoma. *Arch Intern Med* 157:901-906, 1997
46. Fernandez-Cruz L, Taura P, Saenz A, et al: Laparoscopic approach to pheochromocytoma: Hemodynamic changes and catecholamine secretion. *World J Surg* 20:762-768, 1996
47. Roizen MF, Schreider BD, Hassan SZ: Anesthesia for patients with pheochromocytoma. *Anesthesiol Clin North Am* 5:269-275, 1987
48. Geoghegan JG, Emberton M, Bloom SR, et al: Changing trends in the management of pheochromocytoma. *Br J Surg* 85:117-120, 1998
49. Roizen MF, Hunt TK, Beaupre PN, et al: The effect of alpha-adrenergic blockade on cardiac performance and tissue oxygen delivery during excision of pheochromocytoma. *Surgery* 94:941-945, 1983
50. Jovenich JJ: Anesthesia in adrenal surgery. *Urol Clin North Am* 16:583-587, 1989
51. Bravo EL, Gifford Jr RW: Current concepts: Pheochromocytoma: Diagnosis, localization and management. *N Engl J Med* 311:1298-1303, 1984
52. Farid IS, Tetzlaff JE: Preoperative management of pheochromocytoma. *Am J Anesthesiol* 27:156-160, 2000
53. Bergman SM, Sears HF, Javadpour N, et al: Postoperative management of patients with pheochromocytoma. *J Urol* 120:109-112, 1978
54. Witteles RM, Kaplan EL, Roizen MF: Safe and cost-effective preoperative preparation of patients with pheochromocytoma. *Anesth Analg* 91:302-304, 2000
55. Newell KA, Prinz RA, Brooks MH, et al: Plasma catecholamine changes during excision of pheochromocytoma. *Surgery* 104:1064-1073, 1988
56. Orchard T, Grant CS, van Heerden JA, et al: Pheochromocytoma—continuing evolution of surgical therapy. *Surgery* 114:1153-1159, 1993
57. Koriyama N, Kakei M, Yaekura K, et al: Control of catecholamine release and blood pressure with octreotide in a patient with pheochromocytoma: A case report with in vitro studies. *Horm Res* 53:46-50, 2000
58. Munro J, Hurlbert BJ, Hill GE: Calcium channel blockade and uncontrolled blood pressure during pheochromocytoma surgery. *Can J Anaesth* 42:228-230, 1995
59. Proye C, Thevenin D, Cecat P, et al: Exclusive use of calcium channel blockers in preoperative and intraoperative control of pheochromocytomas: Hemodynamics and free catecholamine assays in ten consecutive patients. *Surgery* 106:1149-1154, 1989
60. Joris JL, Hamoir EE, Hartstein GM, et al: Hemodynamic changes and catecholamine release during laparoscopic adrenalectomy for pheochromocytoma. *Anesth Analg* 88:16-21, 1999
61. Sloand EM, Thompson BT: Propranolol-induced pulmonary edema and shock in a patient with pheochromocytoma. *Arch Intern Med* 144:173-174, 1984
62. Perry LB, Gould Jr AB: The anesthetic management of pheochromocytoma effect of preoperative adrenergic blocking drugs. *Anesth Analg* 51:36-40, 1972
63. Dougherty TB, Cronau LH: Anesthetic implications for surgical patients with endocrine tumors. *Int Anesthesiol Clin* 36:31-44, 1998
64. Fox JM, Manninen PH: The anesthetic management of a patient with a pheochromocytoma and acute stroke. *Can J Anaesth* 38:775-779, 1991
65. Mihm FG: Pulmonary artery pressure monitoring in patients with pheochromocytoma. *Anesth Analg* 62:1129-1133, 1983
66. Janeczko GF, Ivankovich AD, Glisson SN, et al: Enflurane anesthesia for surgical removal of pheochromocytoma. *Anesth Analg* 56:62-67, 1977
67. Maze M, Smith CM: Identification of receptor mechanism mediating epinephrine-induced arrhythmias during halothane anesthesia in the dog. *Anesthesiology* 59:322-326, 1983

68. Lippmann M, Ford M, Lee C, et al: Use of desflurane during resection of pheochromocytoma. *Br J Anaesth* 72:707-709, 1994
69. Hull CJ: Pheochromocytoma: Diagnosis, preoperative preparation and anaesthetic management. *Br J Anaesth* 58:1453-1468, 1986
70. Goldfien A: Pheochromocytoma: Diagnosis and anesthetic and surgical management. *Anesthesiology* 24:462-471, 1963
71. Strebel S, Scheidegger D: Propofol-fentanyl anesthesia for pheochromocytoma resection. *Acta Anaesthesiol Scand* 35:275-277, 1991
72. Kerr GE: Pheochromocytoma, in Yao F-SF (ed): Yao and Artusio's *Anesthesiology: Problem-Oriented Patient Management*. Philadelphia, PA, Lippincott-Raven, 1998
73. Kim K, Mondesir L: Severe intraoperative hypertension secondary to unsuspected pheochromocytoma. *Am J Anesthesiol* 28:228-230, 2001
74. Sumikawa K, Amakata Y: The pressor effect of droperidol on a patient with pheochromocytoma. *Anesthesiology* 46:359-361, 1977
75. Smith DS, Aukburg SJ, Levitt JD: Induction of anesthesia in a patient with an undiagnosed pheochromocytoma. *Anesthesiology* 49:368-369, 1978
76. Stoner TR, Urbach KF: Cardiac arrhythmias associated with succinylcholine in a patient with pheochromocytoma. *Anesthesiology* 29:1228-1229, 1968
77. Jones RM, Hill AB: Severe hypertension associated with pancuronium in a patient with a pheochromocytoma. *Can Anaesth Soc J* 28:394-396, 1981
78. Amaranath L, Zanettin GG, Bravo EL, et al: Atracurium and pheochromocytoma: A report of three cases. *Anesth Analg* 67:1127-1130, 1988
79. Humble RM: Pheochromocytoma, neurofibromatosis and pregnancy. *Anaesthesia* 22:296-303, 1967
80. Gencarelli PJ, Roizen MF, Miller RD, et al: ORG NC45 (Norcuron) and pheochromocytoma: A report of three cases. *Anesthesiology* 55:690-693, 1981
81. Roizen MF, Horrigan RW, Koike M, et al: A prospective randomized trial of four anesthetic techniques for resection of pheochromocytoma. *Anesthesiology* 57:A43, 1982
82. Cousins MJ, Rubin RB: The intraoperative management of pheochromocytoma with total epidural sympathetic blockade. *Br J Anaesth* 46:78-81, 1974
83. Mihm FG: Pheochromocytoma: Decreased perioperative mortality. *Anesthesiol Clin North Am* 16:645-662, 1998
84. Bravo EL, Tarazi RC, Gifford RW, et al: Circulating and urinary catecholamines in pheochromocytoma: Diagnostic and pathophysiologic implications. *N Engl J Med* 301:682-686, 1979
85. Vater M, Achola K, Smith G: Catecholamine responses during anaesthesia for pheochromocytoma. *Br J Anaesth* 55:357-360, 1983
86. Cooper ZA, Mihm FG: Blood pressure control with fenoldopam during excision of a pheochromocytoma. *Anesthesiology* 91:558-560, 1999
87. Zakowski M, Kaufman B, Berguson P, et al: Esmolol use during resection of pheochromocytoma: Report of three cases. *Anesthesiology* 70:875-877, 1989
88. Pinto JE, Trifaro JM: The different effects of D-600 (methoxyverapamil) on the release of adrenal catecholamines induced by acetylcholine, high potassium or sodium deprivation. *Br J Pharmacol* 57:127-132, 1976
89. Lenders JW, Sluiter HE, Thien T, et al: Treatment of a pheochromocytoma of the urinary bladder with nifedipine. *BMJ (Clin Res Ed)* 290:1624-1625, 1985
90. Favre L, Forster A, Fathi M, et al: Calcium-channel inhibition in pheochromocytoma. *Acta Endocrinol (Copenh)* 113:385-390, 1986
91. Favre L, Vallotton MB: Nifedipine in pheochromocytoma. *Ann Intern Med* 104:125, 1986
92. Mannelli M, DeFeo ML, Maggi M, et al: Effect of verapamil on catecholamine secretion by human pheochromocytoma. *Hypertension* 8:813-814, 1986
93. Roizen MF: Diseases of the endocrine system, in Benumof JL (ed): *Anesthesia and Uncommon Diseases*. Philadelphia, PA, Saunders, 1998, pp 255-273
94. O'Riordan JA: Pheochromocytoma and anesthesia. *Int Anesthesiol Clin* 35:99-127, 1997
95. Moley JF, Wells SA: Pituitary and adrenal glands, in Townsend JR CM (ed): *Sabiston Textbook of Surgery: The Biological Basis of Modern Surgical Practice*. Philadelphia, PA, Saunders, 2001, pp 671-695
96. Jacobs JK, Goldstein RE, Geer RJ: Laparoscopic adrenalectomy: A new standard of care. *Ann Surg* 225:495-502, 1997
97. Thompson GB, Grant CS, van Heerden JA, et al: Laparoscopic versus open posterior adrenalectomy: A case-control study of 100 patients. *Surgery* 122:1132-1136, 1997
98. Sprung J, O'Hara Jr JF, Gill IS, et al: Anesthetic aspects of laparoscopic and open adrenalectomy for pheochromocytoma. *Urology* 55:339-343, 2000
99. Raeburn CD, McIntyre Jr RC: Laparoscopic approach to adrenal and endocrine pancreatic tumors. *Surg Clin North Am* 80:1427-1441, 2000
100. Janetschek G, Neumann HPH: Advanced urologic laparoscopy. *Urol Clin North Am* 28:97-105, 2001
101. Gagner M, Pomp A, Heniford BT, et al: Laparoscopic adrenalectomy: Lessons learned from 100 consecutive procedures. *Ann Surg* 226:238-247, 1997
102. Pretorius M, Rasmussen GE, Holcomb GW: Hemodynamic and catecholamine responses to a laparoscopic adrenalectomy for pheochromocytoma in a pediatric patient. *Anesth Analg* 87:1268-1270, 1998
103. Inabnet WB, Pitre J, Bernard D, et al: Comparison of the hemodynamic parameters of open and laparoscopic adrenalectomy for pheochromocytoma. *World J Surg* 24:574-578, 2000
104. Bradbury AW: The scope of vascular surgery, in Bannister J, Wildsmith JAW (eds): *Anaesthesia for Vascular Surgery*. London, Arnold, 2000, pp 16-31
105. Hartgrink HH, Roelfsema F, Tollenaar RA, et al: Primary pheochromocytoma extending into the right atrium: Report of a case and review of the literature. *Eur J Surg Oncol* 27:115-119, 2001
106. Sawka AM, Young Jr WF, Schaff HV: Cardiac pheochromocytoma presenting with severe hypertension and chest pain. *Clin Endocrinol (Oxf)* 54:689-692, 2001
107. Ram CVS: Pheochromocytoma. *Cardiol Clin* 6:517-535, 1988
108. Plouin P-F, Chatellier G, Fofol I, et al: Tumor recurrence and hypertension persistence after successful pheochromocytoma operation. *Hypertension* 29:1133-1139, 1997
109. Lewis IH, Yousif D, Mullis SL, et al: Case 2—1994. Management of a cardiac pheochromocytoma in two patients. *J Cardiothorac Vasc Anesth* 8:223-230, 1994
110. Meeke RI, O'Keefe JD, Gaffney JD: Pheochromocytoma removal and postoperative hypoglycemia. *Anaesthesia* 40:1093-1096, 1985
111. Costello GT, Moorthy SS, Vane DW, et al: Hypoglycemia following bilateral adrenalectomy for pheochromocytoma. *Crit Care Med* 16:562-563, 1988
112. Ein SH, Pullerits J, Creighton R, et al: Pediatric pheochromocytoma: A 36-year review. *Pediatr Surg Int* 12:595-598, 1997
113. Nativ O, Grant CS, Sheps SG, et al: Prognostic profile for patients with pheochromocytoma derived from clinical and pathological factors and DNA ploidy pattern. *J Surg Oncol* 50:258-262, 1992
114. Goldfarb DA, Novick AC, Bravo EL, et al: Experience with extra-adrenal pheochromocytoma. *J Urol* 142:931-936, 1989
115. Nativ O, Grant CS, Sheps SG, et al: The clinical significance of nuclear DNA ploidy pattern in 184 patients with pheochromocytoma. *Cancer* 69:2683-2687, 1992